Pearls in Liver Imaging

Gory Ballester Ortiz, MD

Assistant Professor

Section of Diagnostic Radiology

UPR School of Medicine

Director, Department of Diagnostic Radiology

Hospital Español Auxilio Mutuo

Nothing to disclose

Objectives

- Overview of LI-RADS
- Indications, strengths, weaknesses of US, CT, MRI in liver disease
- Review cases of liver pathology
- Be aware of state-of-the-art imaging options for liver imaging

Outline

- Diffuse liver disease
- Non-alcoholic fatty liver disease
- Chronic liver disease
- LI-RADS
  - US
  - CT/MRI
- Cases
- Hepatobiliary contrast (Eovist)
- Advances in liver imaging

Diffuse Liver Disease

Storage	Inflammatory	Vascular
• NAFLD • Iron overload • Wilson disease • Glycogen storage • Muccopolysaccaharidosis	• Viral hepatitis • Autoinmune • Sarcoidosis	• Portal vein thrombosis • Bud-Chiari • Hepatic artery occlusion • Preclampsia-Eclampsia • Congestive heart Failure

Diffuse Liver Disease

- Chronic liver disease is a spectrum
  - Insult/Injury – inflammation – fibrosis – cirrhosis

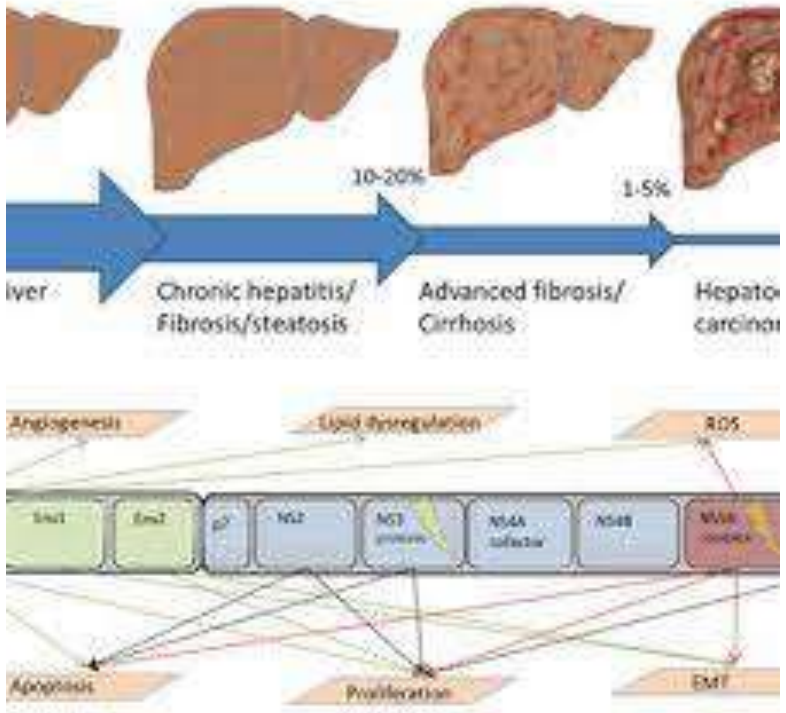

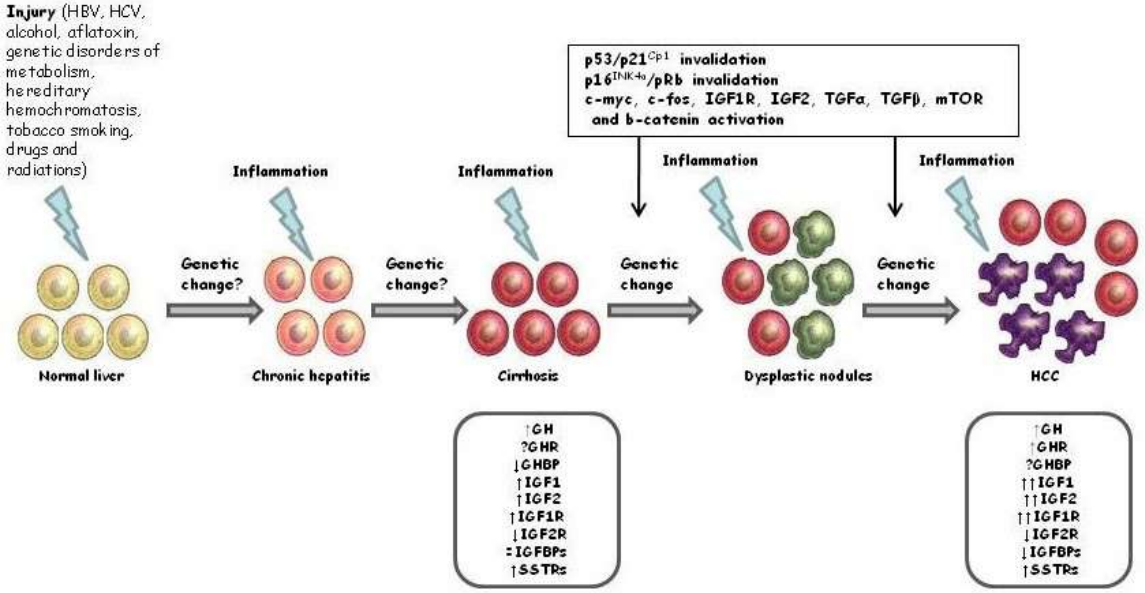

Diffuse Liver Disease

- Imaging features may hold clues to etiology

Non-alcoholic fatty liver disease (NAFLD)

NAFLD

- NASH cirrhosis is a leading indication for liver transplantation.
    - Global health problem: up to a billion people affected

NAFLD

- US
  - Widely available
  - No radiation
  - Operator dependent
  - Machine capabilities dependent
  - Hepatorenal index
  - Vessel blurring
  - Modest performance
    - 50-62% sensitive for steatosis >5%

Hong CW, Abd Rad 2019

Hepatic steatosis US

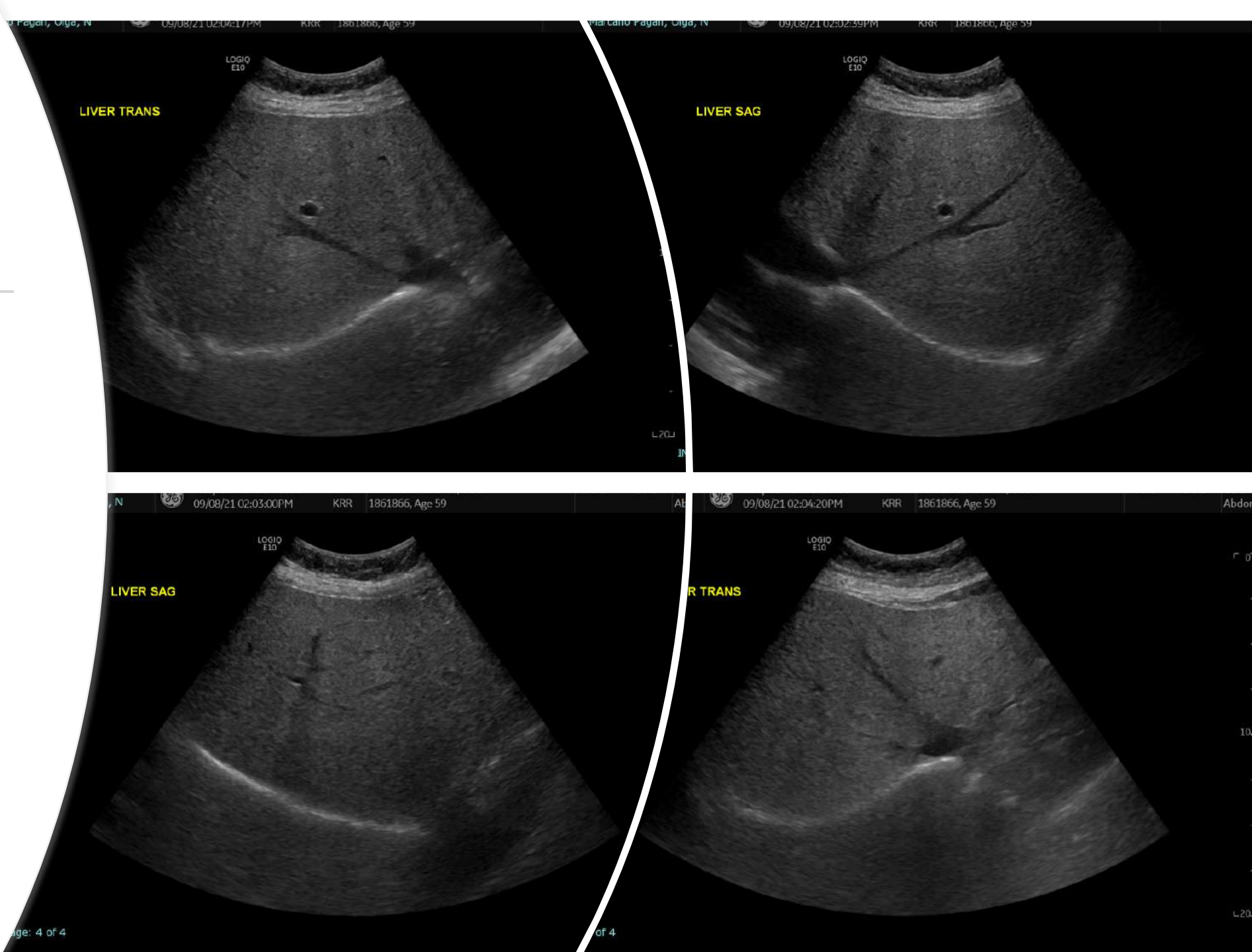

NAFLD

- CT
  - HU<40
  - Liver HU-Spleen HU
  - Areas of sparing (falciform ligament, gallbladder)
  - Not quantitative
  - Not accurate for mild steatosis
  - Dependent on tube voltage

Byun J, Eur Rad 2019

Hepatic steatosis - CT

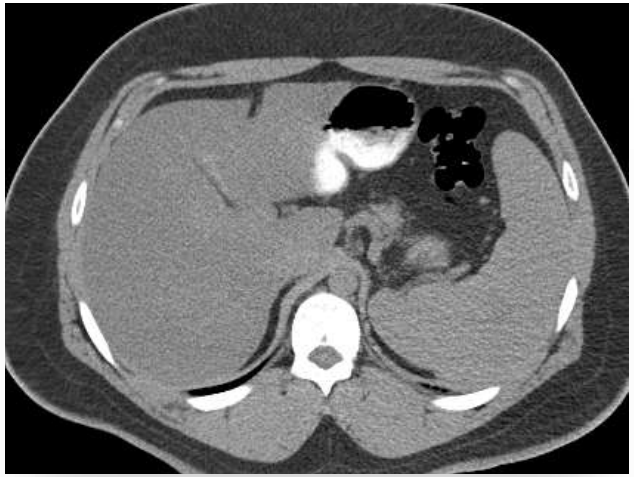

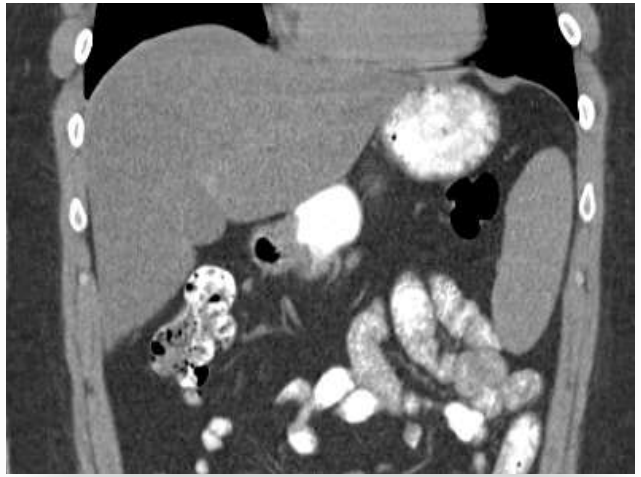

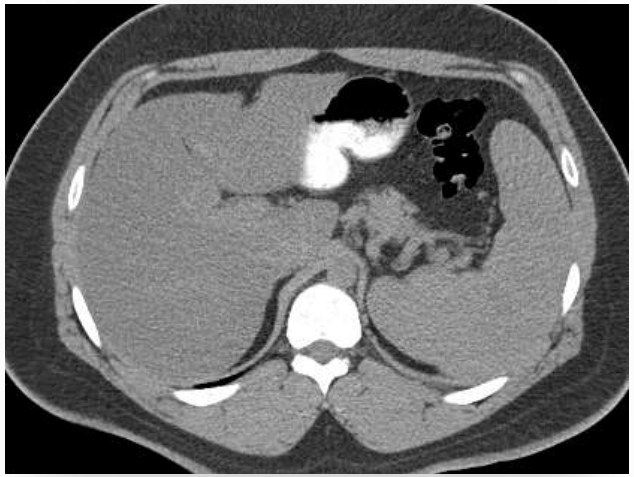

NAFLD - Hepatic steatosis with focal fatty sparing

NAFLD - CLD

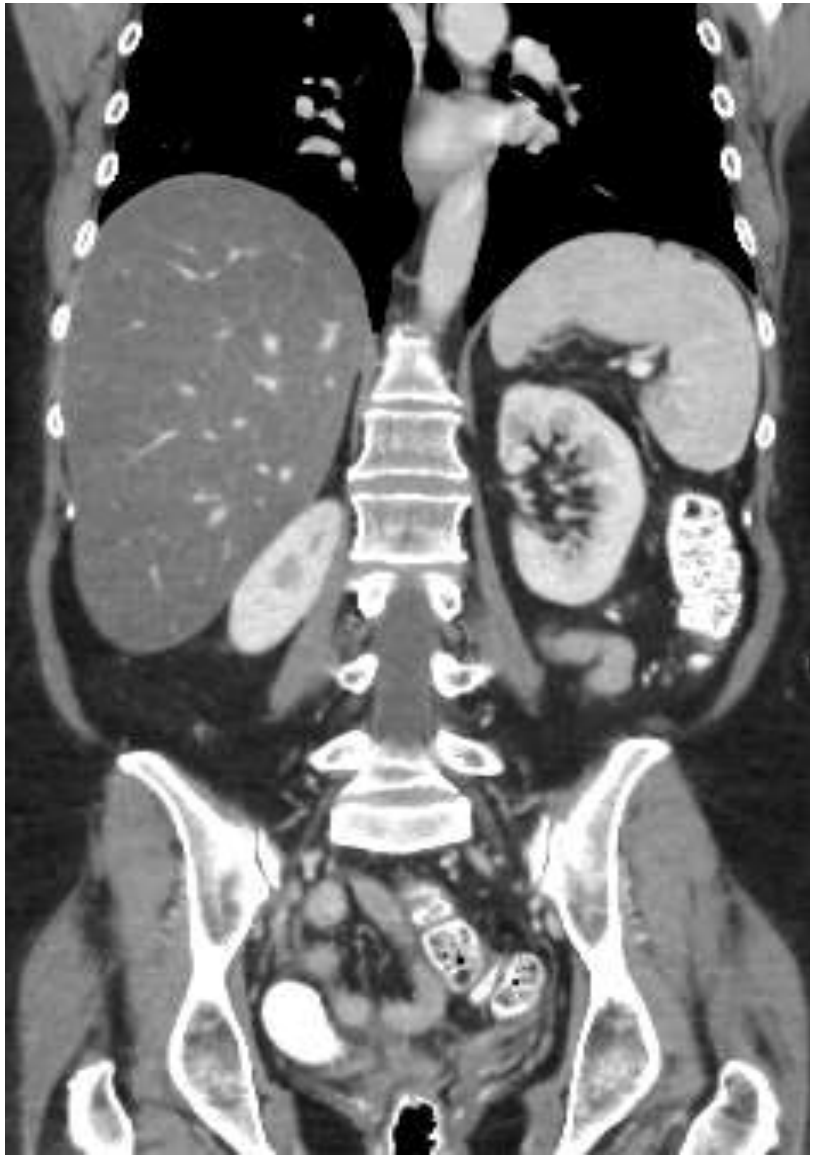

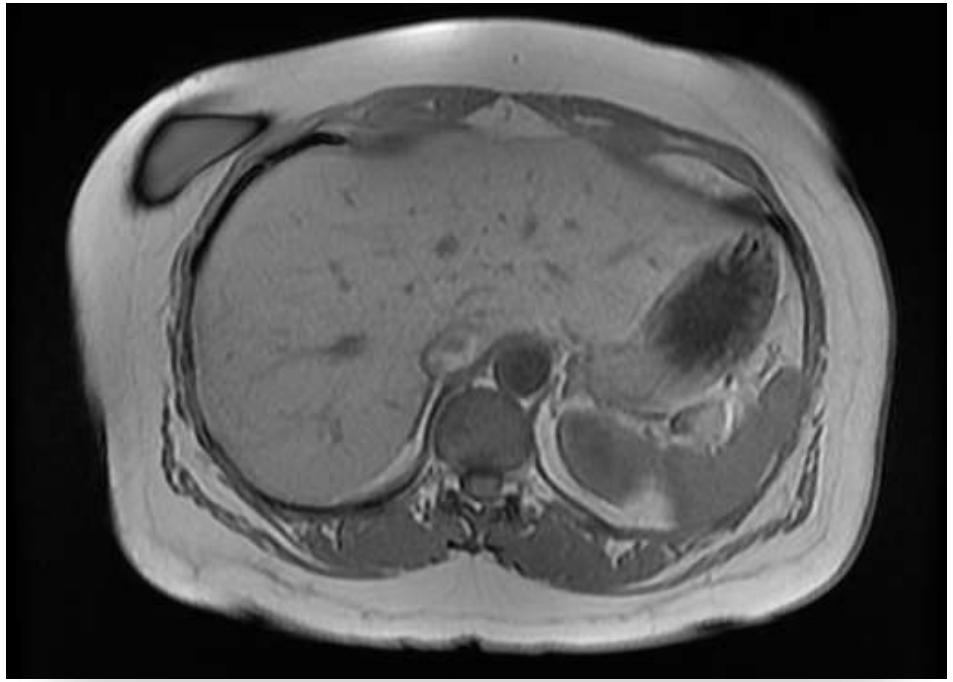

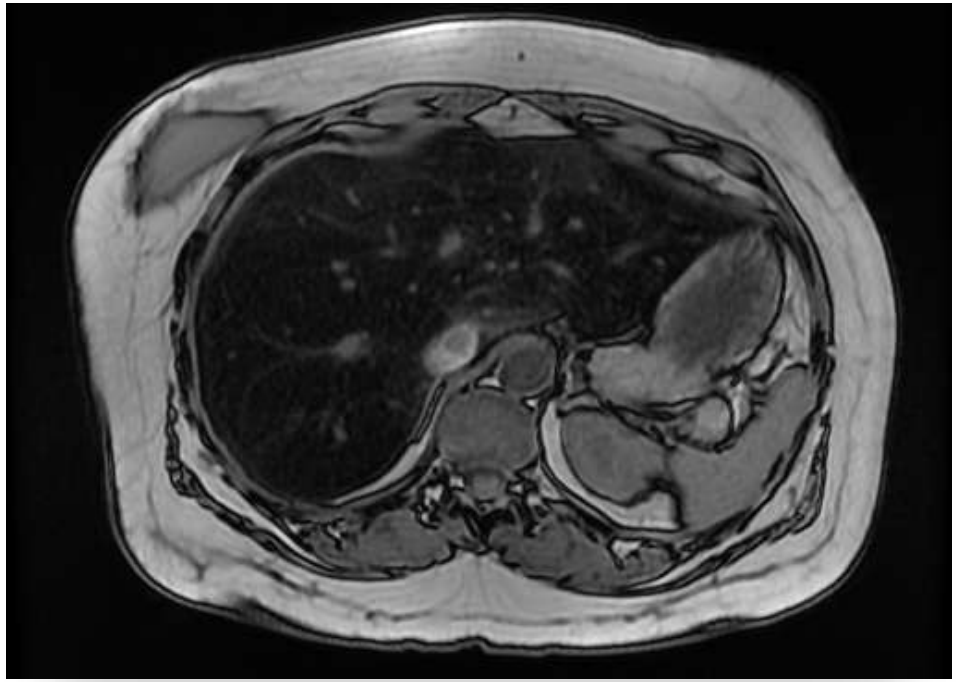

Hepatic steatosis - MRI

In-phase, Out-of-phase

Chronic liver disease

- Volumetric redistribution (caudate and segment IV hypertrophy)
- Surface nodularity
- Expansion of perihilar space
- Global atrophy
- Confluent fibrosis
- Varices

Cirrhosis

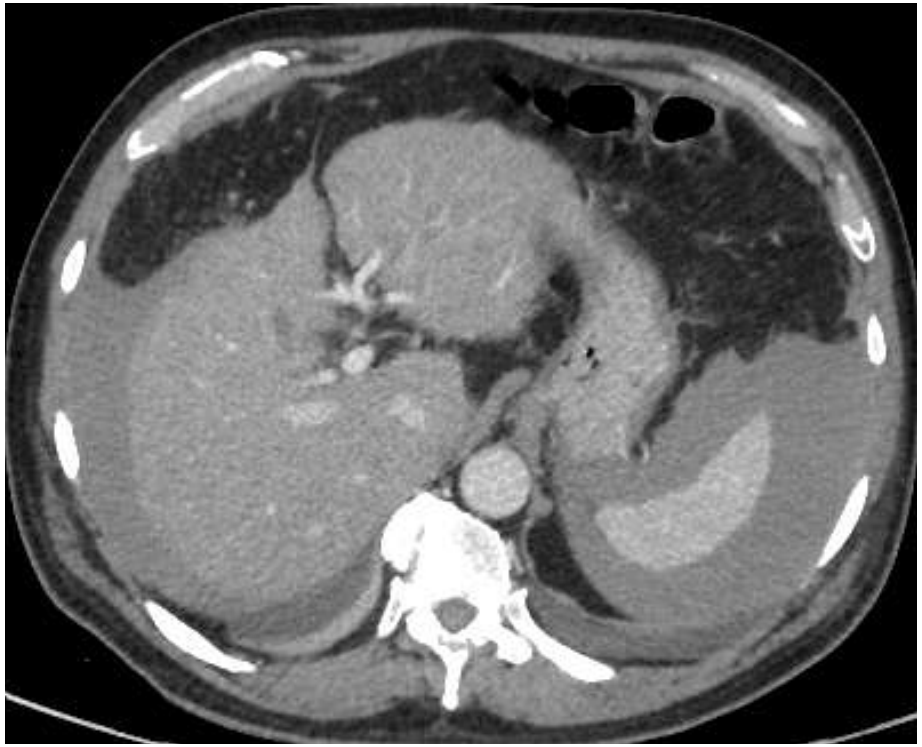

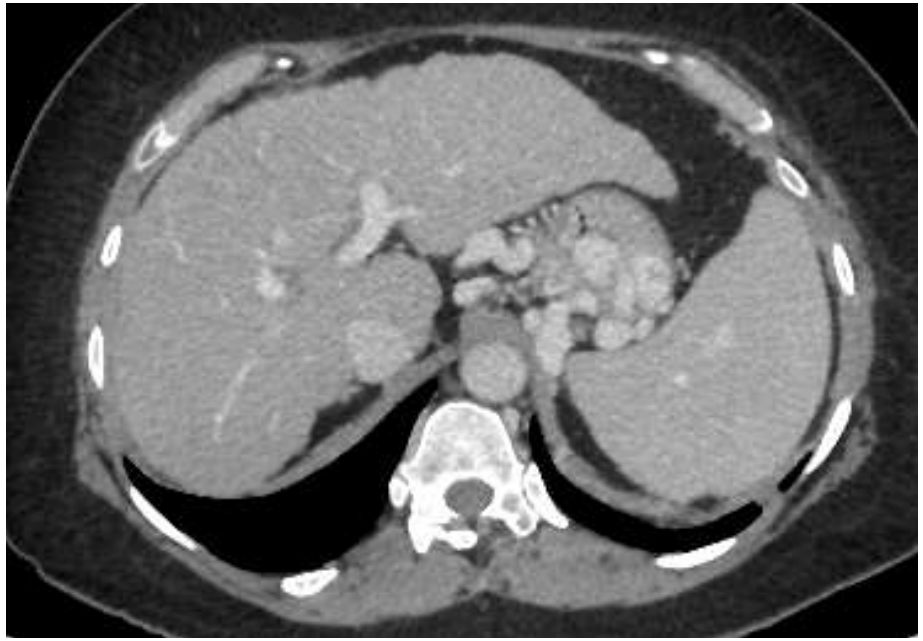

LI-RADS (liver reporting and data system)

LI-RADS

- 2006, UCSD
- Reports
  - “Indeterminate”, “equivocal”, “supicious”, “HCC should be considered”, “worrisome for HCC”, “may represent HCC”, “possibly representing HCC”, “HCC not excluded”, “can’t exclude cancer”, “unclear relevance”, “uncertain significance”, “clinical correlation recommended”
  - Ambiguous and not actionable reports

- V1.0 – 2011
- V2018 last
  - LI-RADS supported by AASLD

- >250 contributors, >30 institutions, >30 countries

LI-RADS

- System for standardized imaging for liver cancer
- Standardizes
  - Terminology
  - Technique
  - Interpretation
  - Reporting
  - Data collection
- Algorithms
    - US LI-RADS – surveillance of HCC
    - CEUS LI-RADS – diagnosis of HCC
    - CT/MRI LI-RADS –diagnosis and staging of HCC
    - CT/MRI tx response LI-RADS – assessing response of HCC to LRT
    - In development…
      - CEUS tx response
      - Sistemic tx response
- Improved communication, patient care, education and research
- Multidisciplinary consortium
- Dynamic

LI-RADS v2018 manual

LI-RADS: Four imaging algorithms

- Screening and surveillance algorithm
  - US
- Diagnosis
  - CT
  - MRI
  - CEUS
- Treatment response assessment
  - CT
  - MRI
  - CEUS

US for liver evaluation

Ultrasound for liver evaluation

Advantages

- Not expensive
- “Accessible”
- No radiation

Limitations

- Operator dependent
- Limited reproducibility
- Pts with large body habitus and uncooperative
- Limited acoustic window
- Reduced beam penetration
- Parenchymal heterogeneity

Ultrasound for liver evaluation

US LI-RADS® v2017 CORE

Screening or surveillance US in patient at high risk for HCC

US category

US-1	Negative
US-2	Subthreshold
US-3	Positive

Category	Concept	Definition
US-1 Negative	No US evidence of HCC	No observation **OR** Only definitely benign observation(s)
US-2 Subthreshold	Observation(s) detected that may warrant short-term US surveillance	Observation(s) < 10 mm in diameter, not definitely benign
US-3 Positive	Observation(s) detected that may warrant multiphase contrast-enhanced imaging	Observation(s) ≥ 10 mm in diameter, not definitely benign **OR** New thrombus in vein

US visualization score

A	No or minimal limitations
B	Moderate limitations
C	Severe limitations

Score	Concept	Examples
A. No or minimal limitations	Limitations if any are unlikely to meaningfully affect sensitivity	Liver homogeneous or minimally heterogeneous Minimal beam attenuation or shadowing Liver visualized in near entirety
B. Moderate limitations	Limitations may obscure small masses	Liver moderately heterogeneous Moderate beam attenuation or shadowing Some portions of liver or diaphragm not visualized
C. Severe limitations	Limitations significantly lower sensitivity for focal liver lesions	Liver severely heterogeneous Severe beam attenuation or shadowing Majority (>50%) of liver not visualized Majority (>50%) of diaphragm not visualized

LI-RADS v2018 manual

US LI-RADS v2017

Recommended screening and surveillance populations include:

- Patients with cirrhosis of any etiology
- Noncirrhotic HBV Asian male > 40
- Noncirrhotic HBV Asian female > 50
- Noncirrhotic African/North American Blacks with HBV
- Noncirrhotic HBV patients with family history of HCC

Depending on geographic region, patients may be enrolled in an HCC screening and surveillance program if they have any of the following:

- Adults with cirrhosis of any cause
- Some adults with chronic hepatitis B viral infection even in the absence of cirrhosis
- Some adults with chronic hepatitis C viral infection even in the absence of cirrhosis

LI-RADS v2018 manual

US LI-RADS v2017

Do not apply in patients:

- Without the above risk factors
- < 18 years old
- With cirrhosis due to congenital hepatic fibrosis
- With cirrhosis due to a vascular disorder such as hereditary hemorrhagic telangiectasia, Budd-Chiari syndrome, chronic portal vein occlusion, cardiac congestion, or diffuse nodular regenerative hyperplasia

LI-RADS v2018 manual

Ultrasound

US LI-RADS® Recommended US Views

Longitudinal images

Recommended views	Left lobe: • left of midline • at midline; include proximal abdominal aorta, celiac artery, and SMA • with IVC; include caudate lobe, MPV, and pancreatic head • with left portal vein Right lobe: • with gallbladder • with right kidney • including right hemidiaphragm and adjacent pleural space • far lateral Main portal vein; include grayscale and color Doppler Common bile duct at porta hepatis; include diameter measurement
Optional views	Color Doppler of the right and left portal veins, and hepatic veins Spectral Doppler of main portal vein to assess waveform, velocity, and flow direction

Transverse images

Recommended views	Dome with hepatic veins; include entire right and left lobe with medial and lateral liver edges (on separate images as needed) Left lobe: • with left portal vein • falciform ligament to evaluate for the presence of patent paraumbilical vein Main portal vein bifurcation Right lobe: • with right portal vein • with main portal vein • with gallbladder • with right kidney • near liver tip
Optional views	Color Doppler view of additional vascular structures

Cine loops

Recommended views	—
Optional views	Longitudinal and transverse cine sweeps of left and right lobes, including as much hepatic parenchyma as possible

LI-RADS v2018 manual

Ultrasound

US LI-RADS® Management Summary

US-1 Negative	Repeat surveillance US in 6 mo
US-2 Subthreshold	Repeat surveillance US in 3-6 mo [a,b]
US-3 Positive	Further characterization with multiphase contrast-enhanced imaging [c]

LI-RADS v2018 manual

LI-RADS® v2017
US Core

Ultrasound

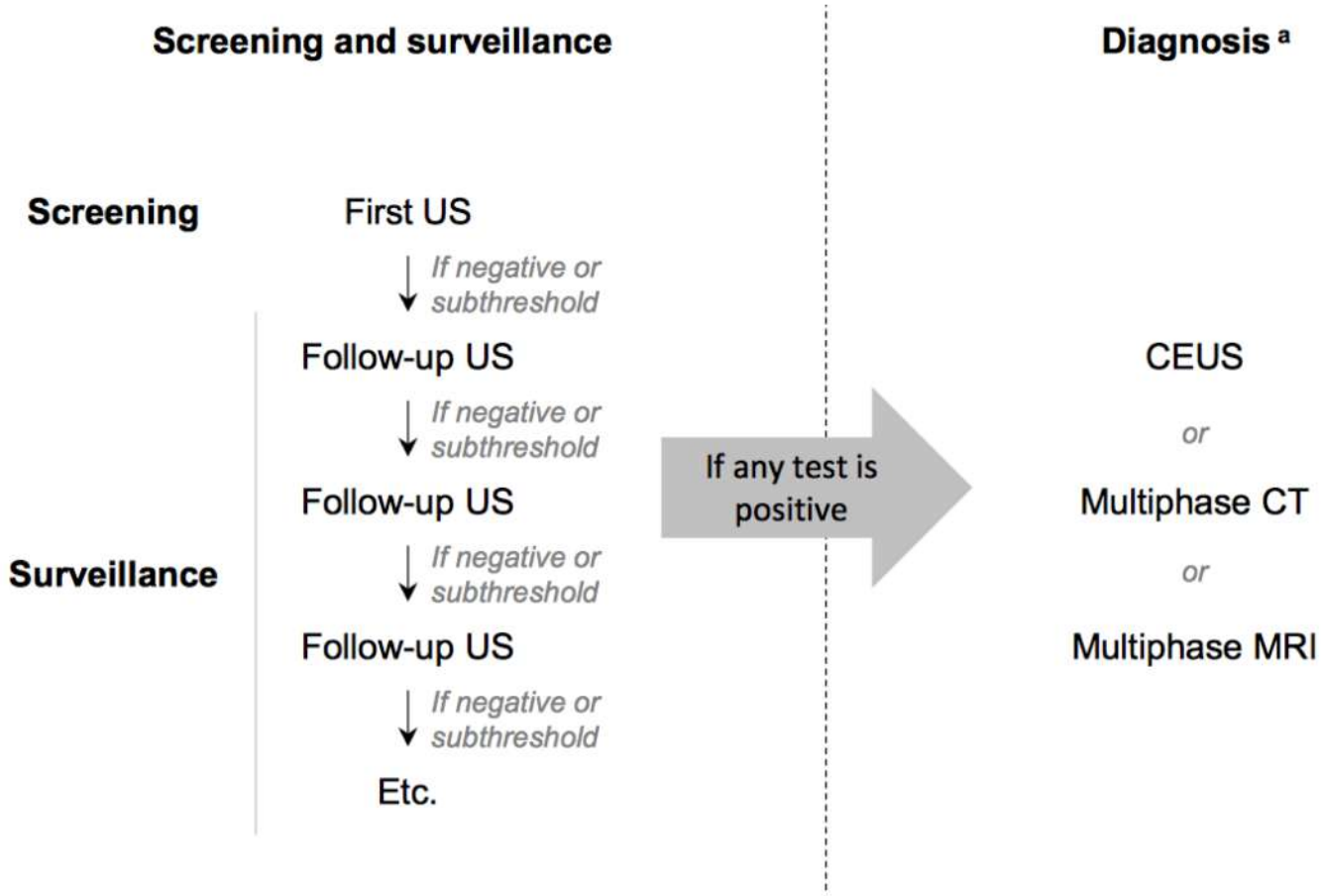

LI-RADS v2018 manual

Contrast enhanced Ultrasound

- IV injected microbubble contrast agents
- Dynamic characterization of lesion and liver blood flow
- High temporal resolution
- Real time imaging
- Not for entire liver
- Problem solving

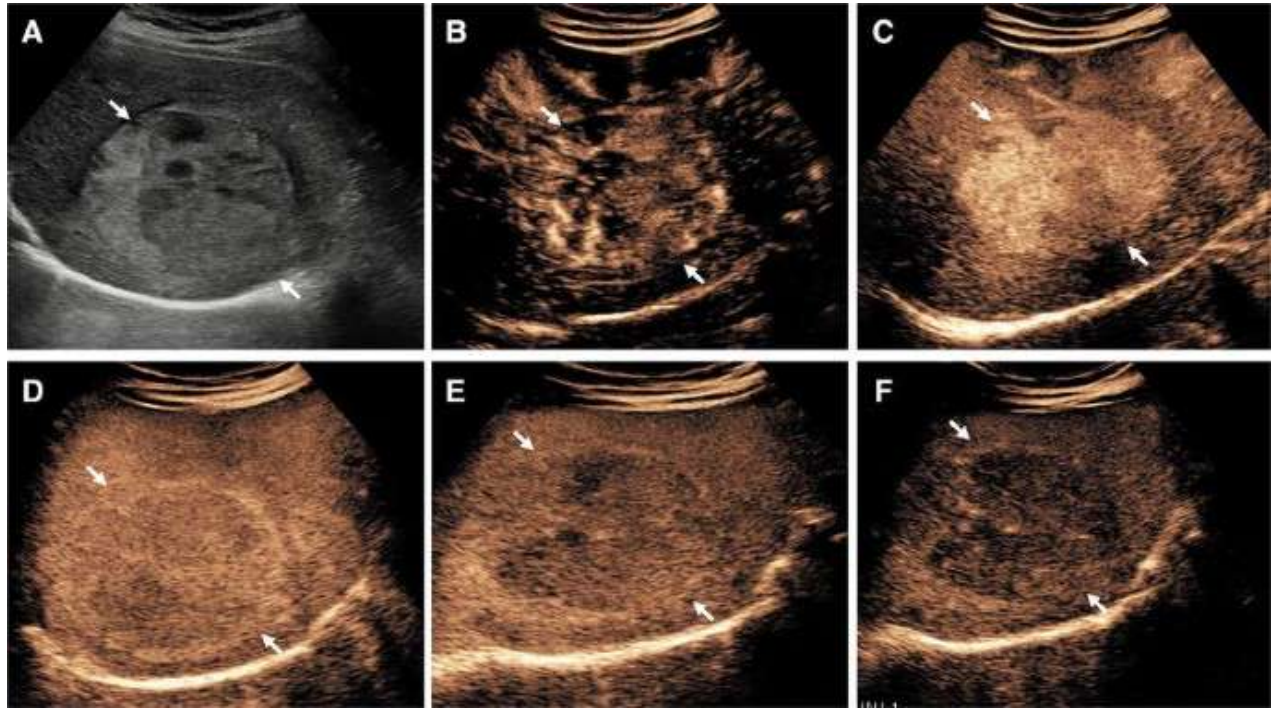

CT and MRI for liver evaluation

CT/MRI for liver evaluation

CT

- Temporal resolution
- Fast study
- Widely available

MRI

- Contrast resolution
- Artifacts
  - Breathing
  - Peristalsis
  - Ascites
- Long study
- Expensive
  - Insurances

CT/MR LI-RADS v2018 Technical Recommendations

CT

Recommended equipment	• Multidetector CT with ≥ 8 detector rows
Required images	• Arterial phase (late arterial phase strongly preferred) • Portal venous phase • Delayed phase
Suggested images	• Precontrast, if patient has had locoregional treatment • Multiplanar reformations

LI-RADS® v2018
CT/MRI Core

CT/MR LI-RADS v2018 Technical Recommendations

MRI with extracellular contrast agents or gadobenate dimeglumine

Recommended equipment	• 1.5T or 3T • Torso phased-array coil

Required images	• Unenhanced T1-weighted OP and IP imaging
	• T2-weighted imaging (fat suppression per institutional preference)
	• Multiphase T1-weighted imaging
	  • Precontrast imaging
	  • Arterial phase (late arterial phase strongly preferred)
	  • Portal venous phase
	  • Delayed phase

Suggested or optional images	• Diffusion-weighted imaging • Subtraction imaging • Multiplanar acquisition • 1- to 3-hr hepatobiliary phase with gadobenate dimeglumine (same sequence type as for multiphase, may use higher flip angle to increase T1 contrast)

CT/MR LI-RADS v2018 Technical Recommendations

MRI with gadoxetate disodium

Recommended equipment	• 1.5T or 3T • Torso phased-array coil

Required images	• Unenhanced T1-weighted OP and IP imaging
	• T2-weighted imaging (fat suppression per institutional preference)
	• Multiphase T1-weighted imaging
	  • Precontrast imaging
	  • Arterial phase (late arterial phase strongly preferred)
	  • Portal venous phase
	  • Transitional phase (2 to 5 minutes after injection)
	  • Hepatobiliary phase (same sequence type as for earlier phases, may use higher flip angle to increase T1 contrast)

Suggested or optional images	• Diffusion-weighted imaging • Subtraction imaging • Multiplanar acquisitions

CT/MRI
LI-RADS

CT/MRI LI-RADS® v2018

Apply in patients at high risk for HCC, namely those with:

- Cirrhosis **OR**
- Chronic hepatitis B viral infection **OR**
- Current or prior HCC

Including adult liver transplant candidates and recipients posttransplant

Do not apply in patients:

- Without the above risk factors
- < 18 years old
- With cirrhosis due to congenital hepatic fibrosis
- With cirrhosis due to a vascular disorder such as hereditary hemorrhagic telangiectasia, Budd-Chiari syndrome, chronic portal vein occlusion, cardiac congestion, or diffuse nodular regenerative hyperplasia

LI-RADS® v2018
CT/MRI Core

LI-RADS

- Observations: distinctive when compared to background liver
- 8 diagnostic categories

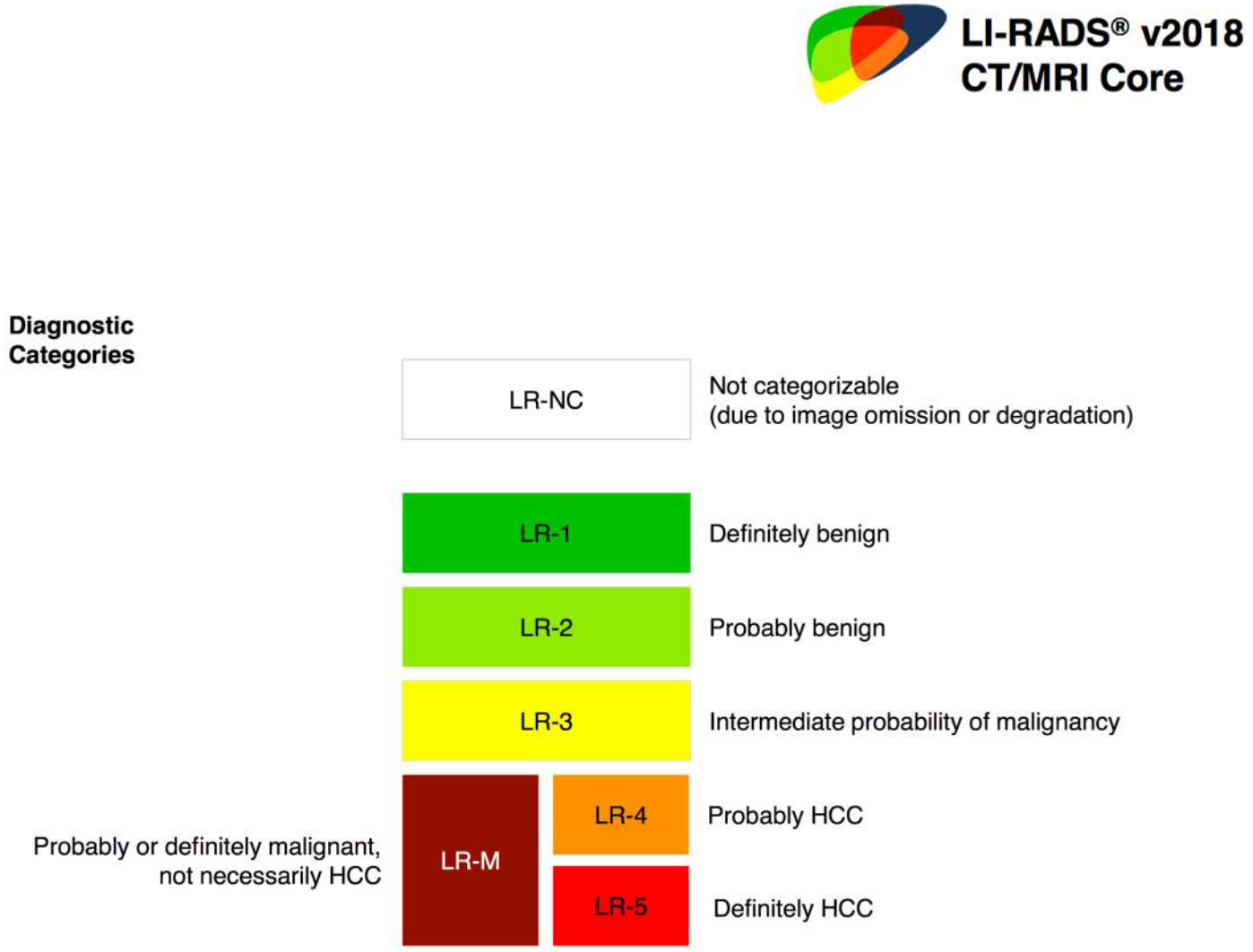

LI-RADS

CT/MRI LI-RADS® v2018 CORE

Untreated observation without pathologic proof in patient at high risk for HCC

- If cannot be categorized due to image degradation or omission → LR-NC
- If definite tumor in vein (TIV) → LR-TIV
- If definitely benign → LR-1
- If probably benign → LR-2
- If probably or definitely malignant but not HCC specific (e.g., if targetoid) → LR-M

Otherwise, use CT/MRI diagnostic table below

- If intermediate probability of malignancy → LR-3
- If probably HCC → LR-4
- If definitely HCC → LR-5

LI-RADS v2018 manual

LI-RADS

CT/MRI Diagnostic Table

Arterial phase hyperenhancement (APHE)		No APHE		Nonrim APHE		
Observation size (mm)		< 20	≥ 20	< 10	10-19	≥ 20
Count additional major features: • Enhancing "capsule" • Nonperipheral "washout" • Threshold growth	None	LR-3	LR-3	LR-3	LR-3	LR-4
	One	LR-3	LR-4	LR-4	LR-4 / LR-5	LR-5
	≥ Two	LR-4	LR-4	LR-4	LR-5	LR-5

LR-4 / LR-5

Observations in this cell are categorized based on one additional major feature:
- LR-4 – if enhancing "capsule"
- LR-5 – if nonperipheral "washout" **OR** threshold growth

If unsure about the presence of any major feature: characterize that feature as absent

LI-RADS

- LR-3: 31% HCC
- LR-4: 64% HCC
- LR-5: 95% HCC
- LR-M: 99% malignant
  - 33% HCC
  - 65% other malignancy
  - 1% benign

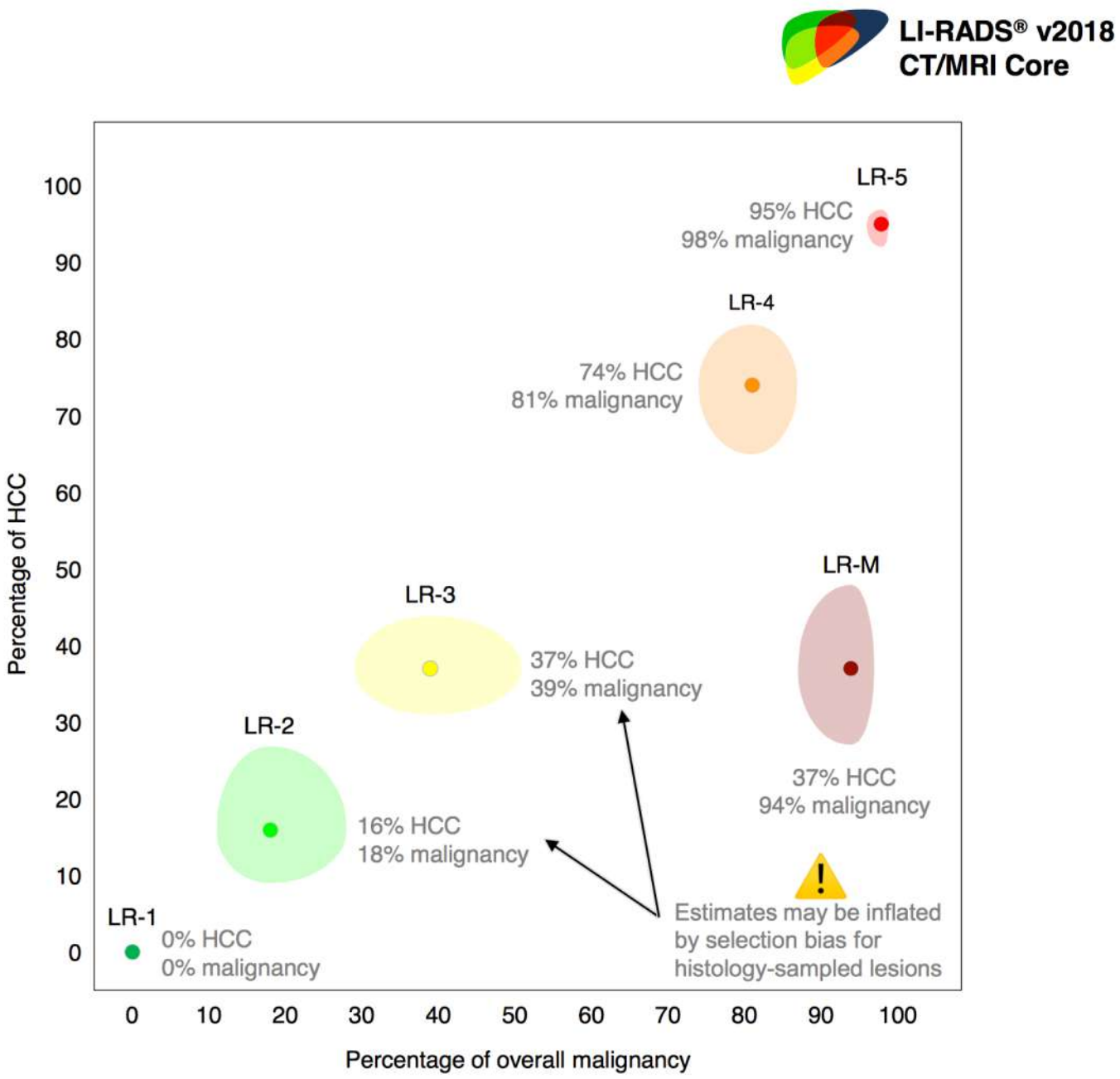

Cases

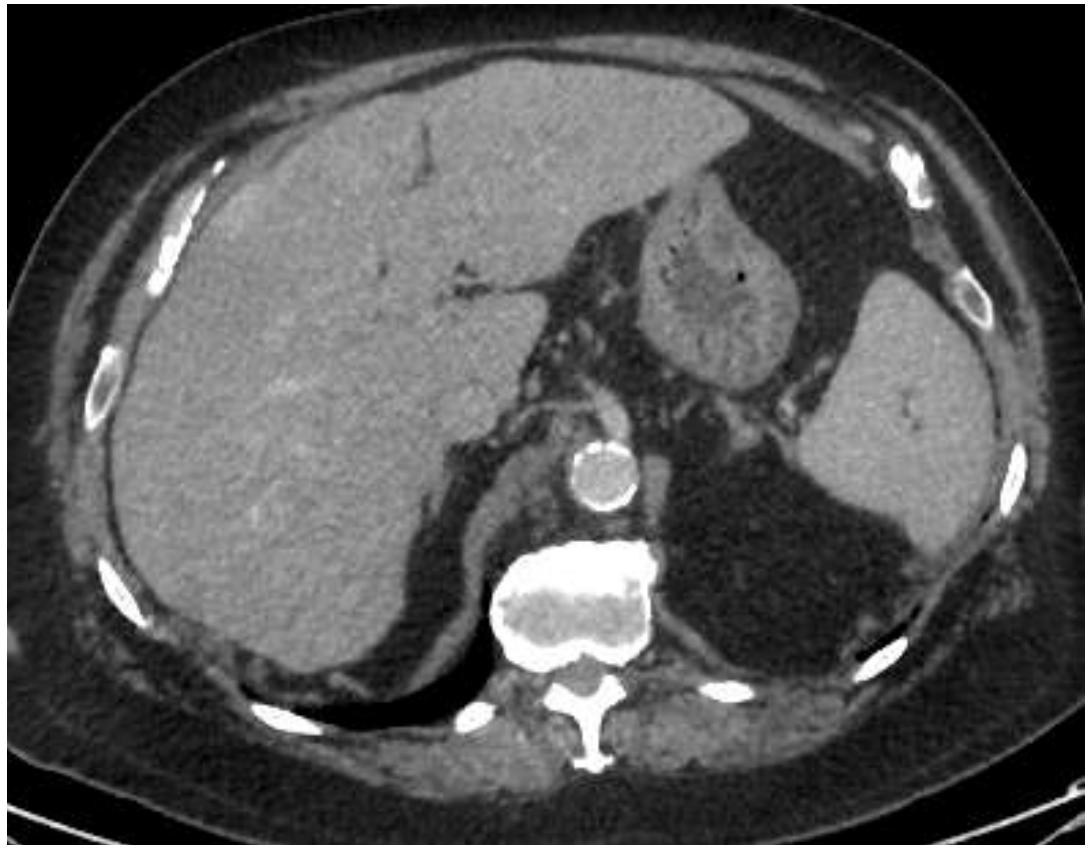

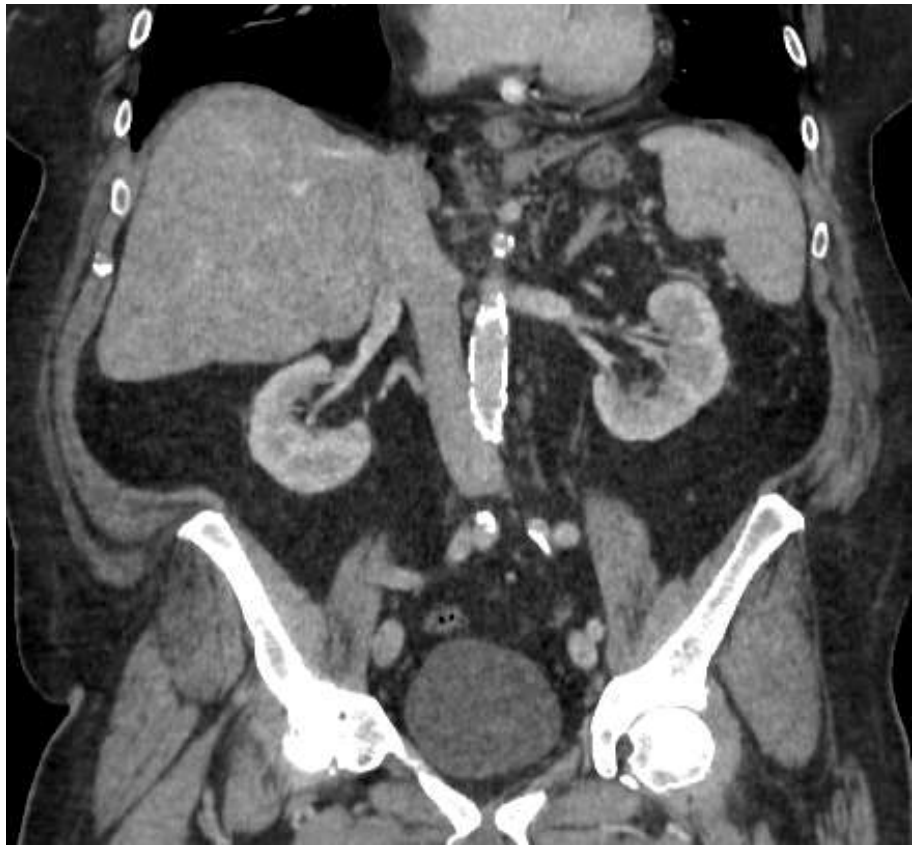

Cirrhotic liver, “heterogeneous enhancement”

LR-TIV

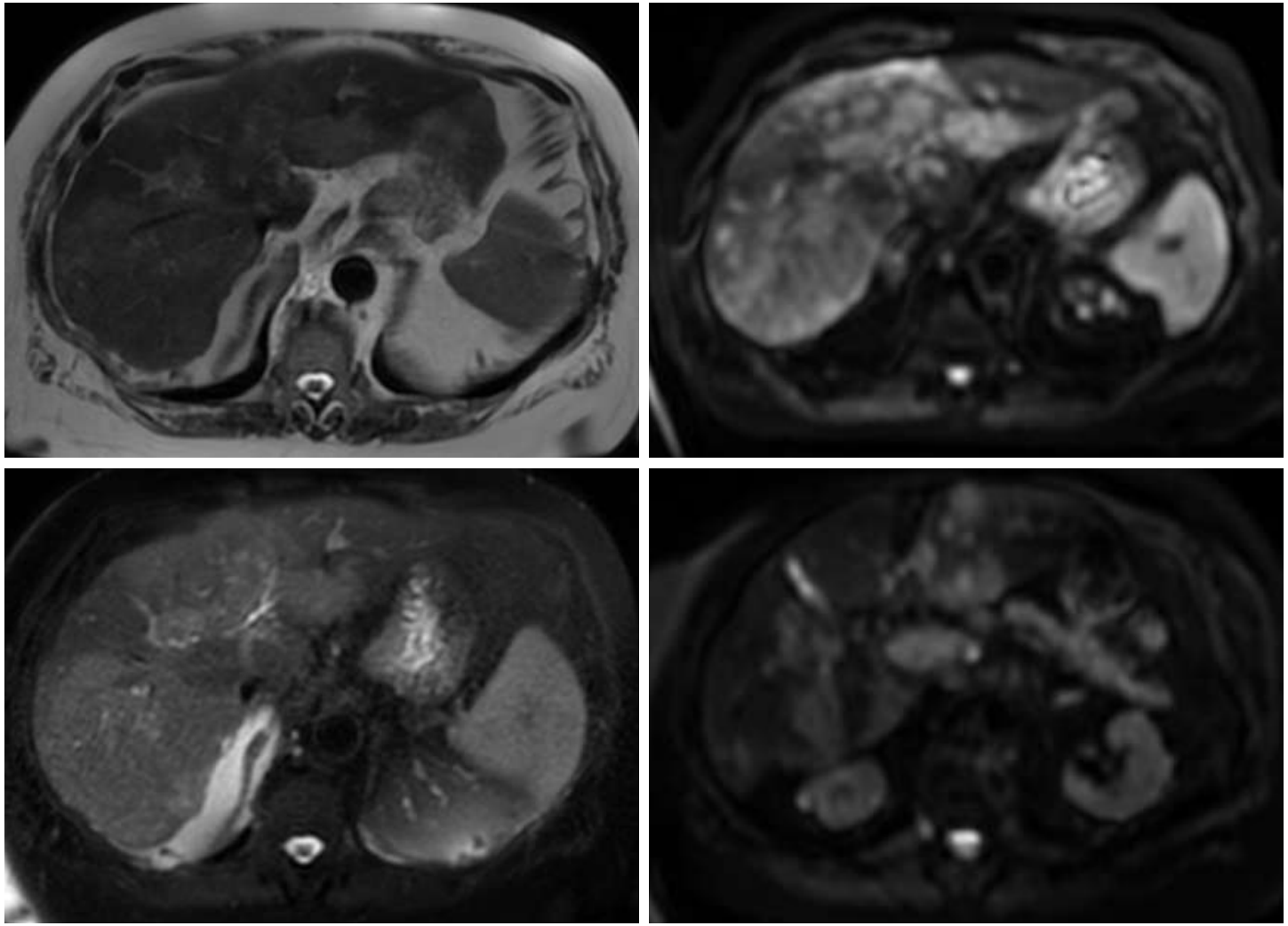

LR-TIV

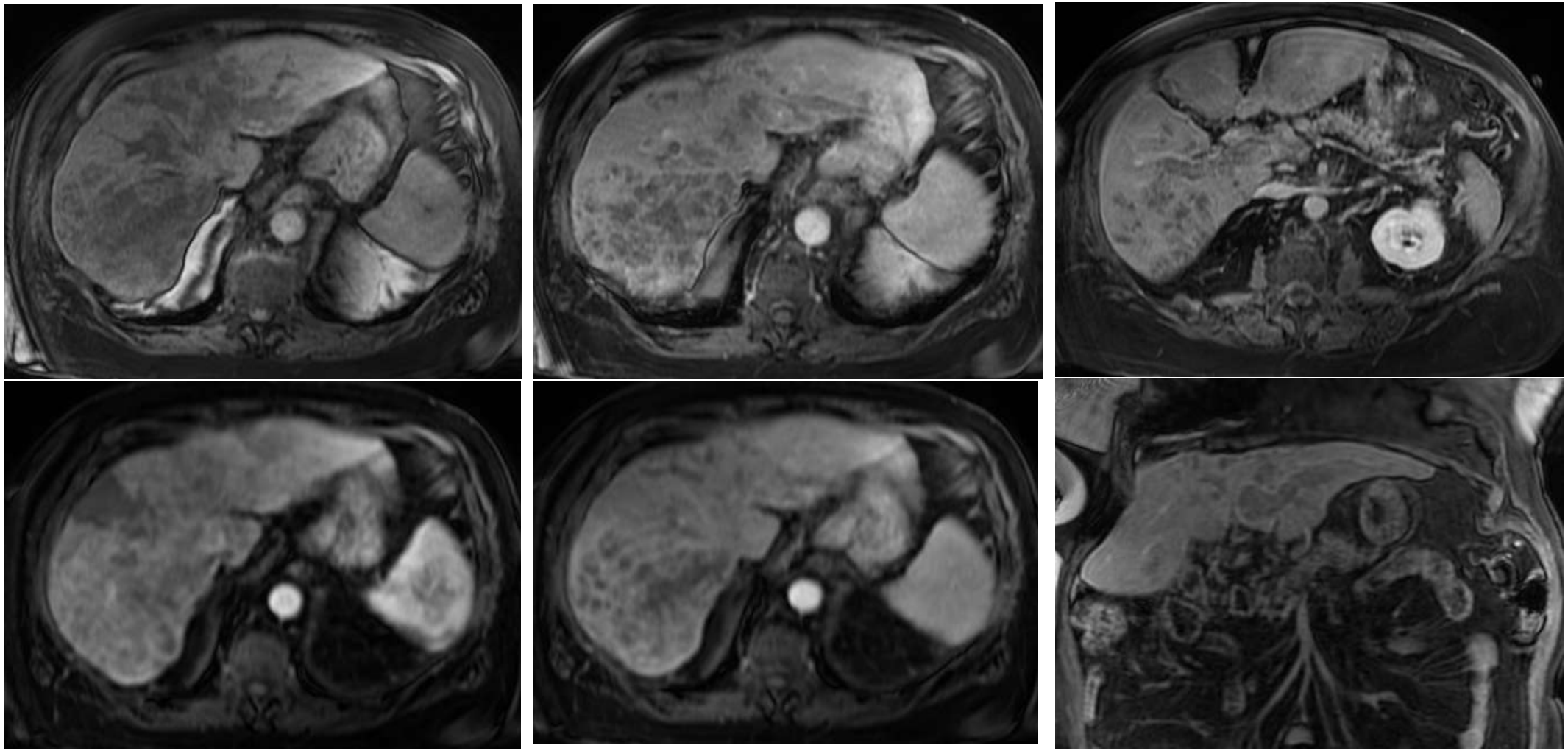

LR-1

- Cysts
- Hemangiomas
- Focal fat
- Arterioportal shunt
- Siderotic nodules
- Hypertrophic pseudomass

Hemangioma; LR-1

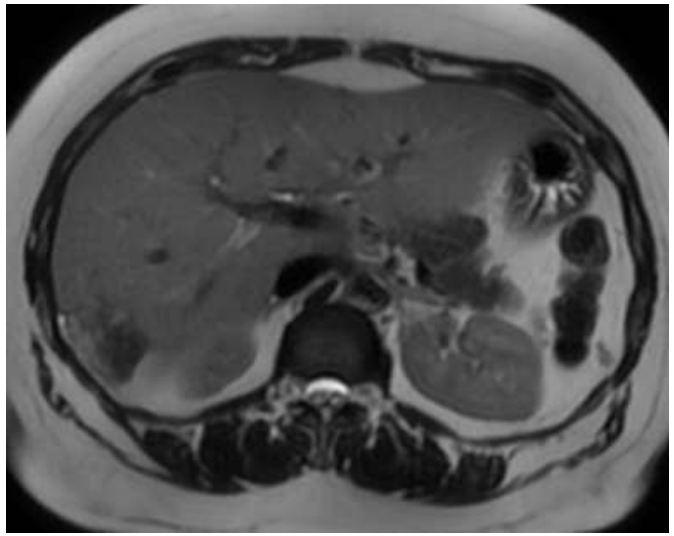
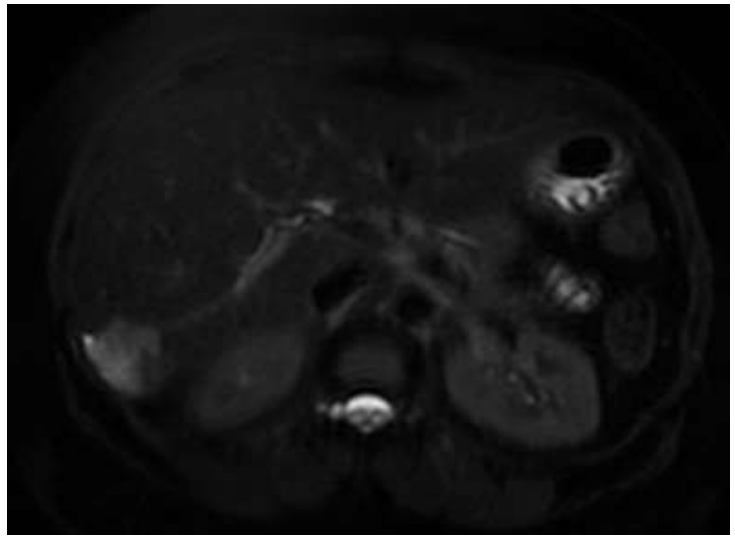
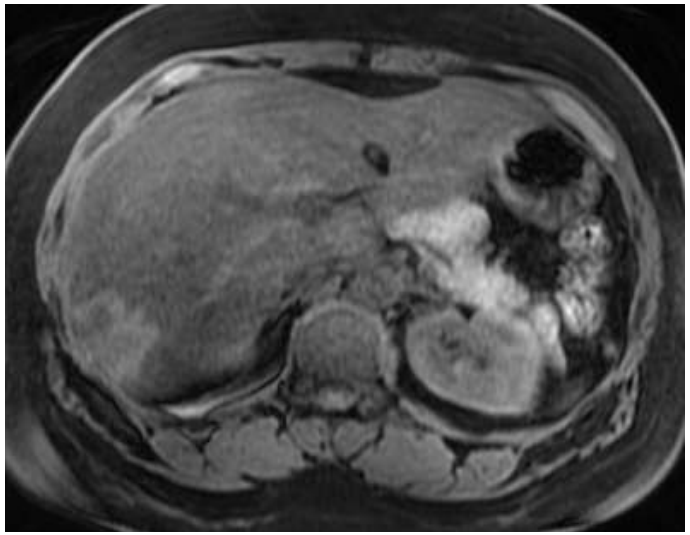
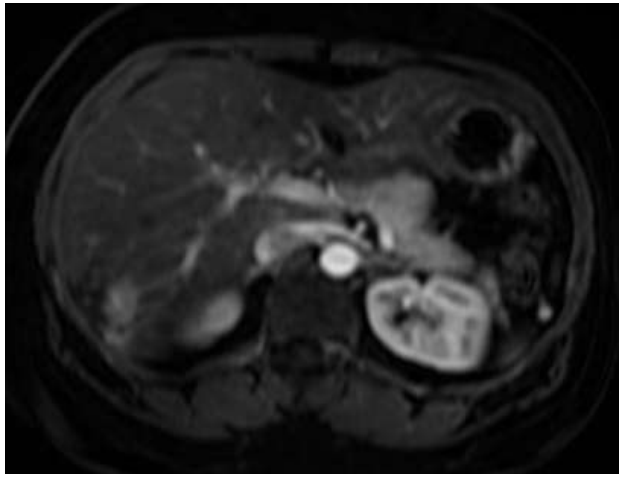
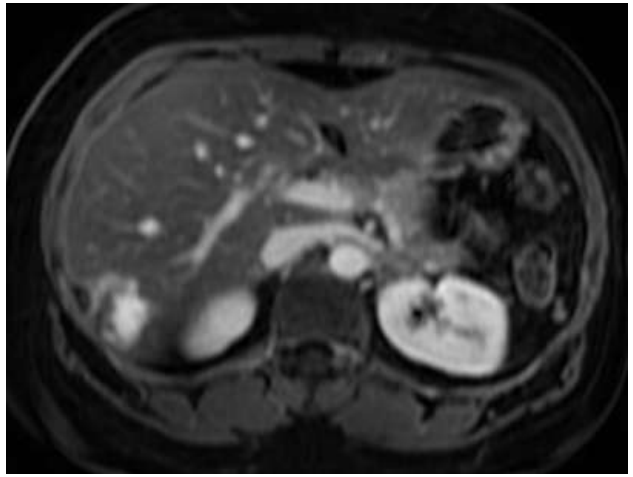
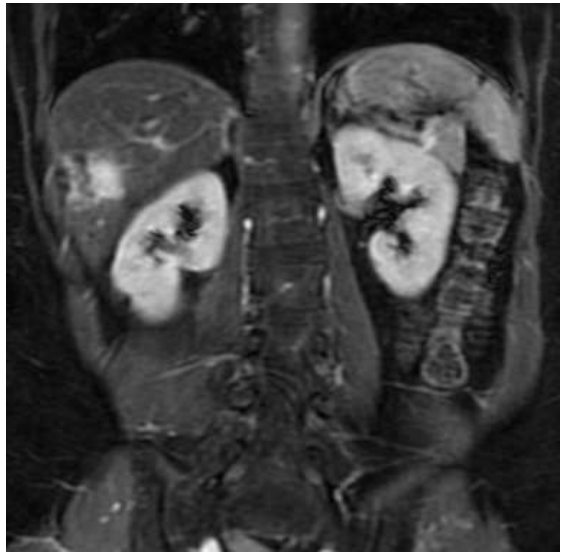
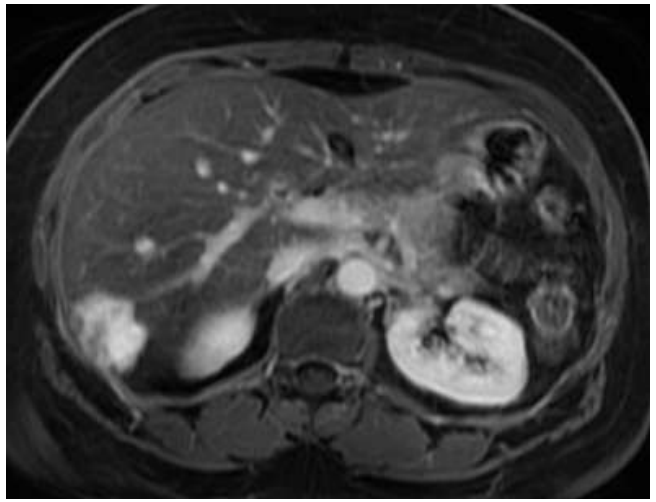

Hemangioma;
LR-1

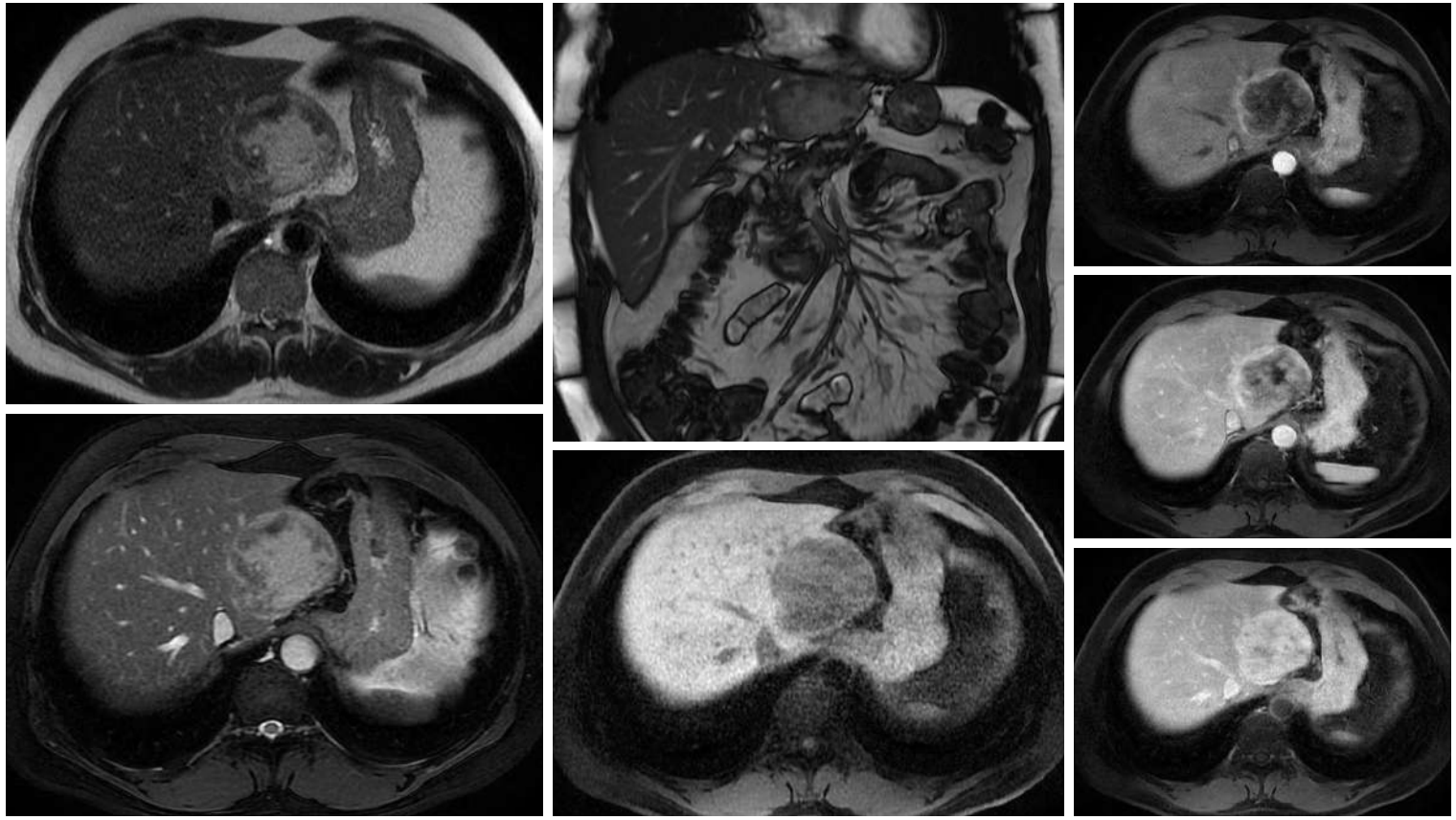

LR-1: Hypertrophic pseudomass - CT

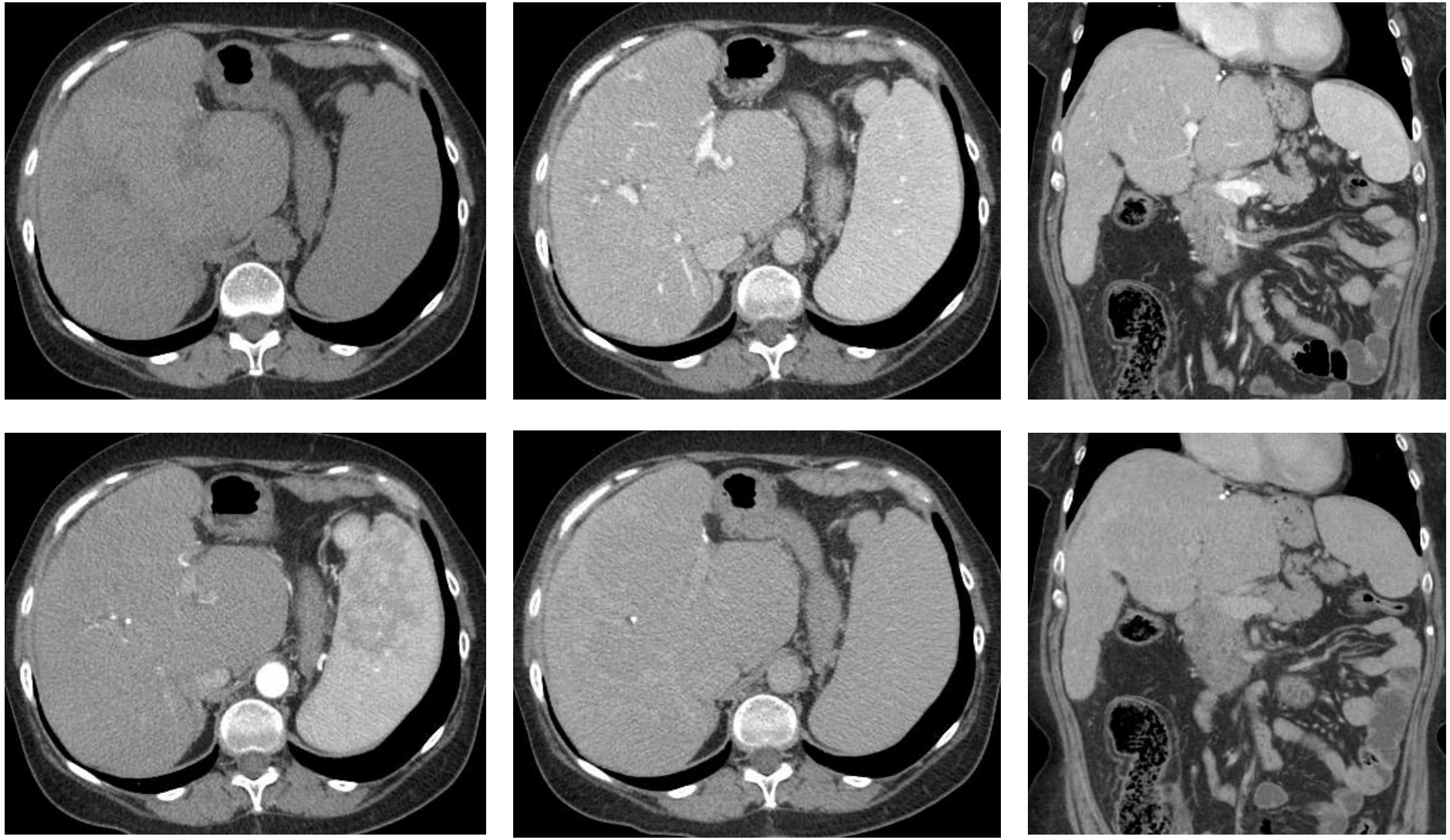

LR-1: Hypertrophic pseudomass - MRI

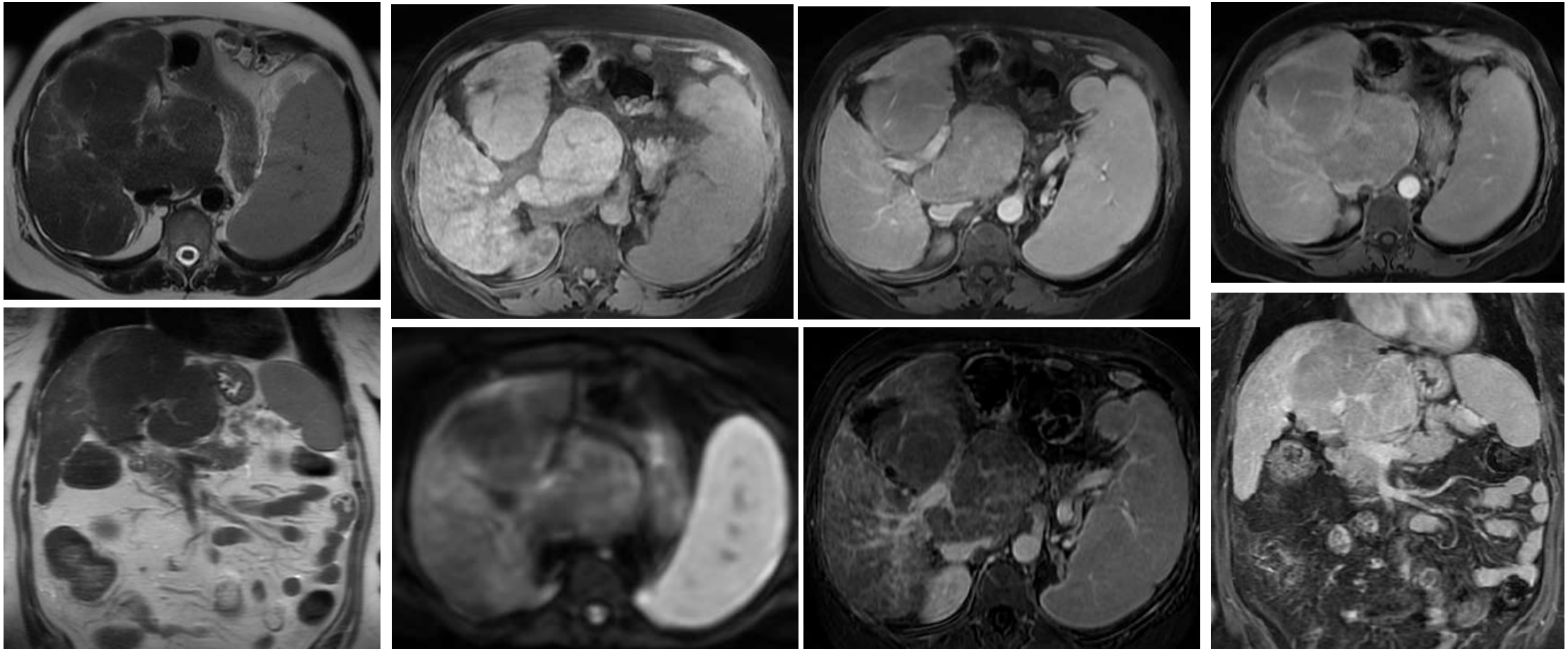

LR-2

Discrete siderotic nodule

Confluent hepatic fibrosis

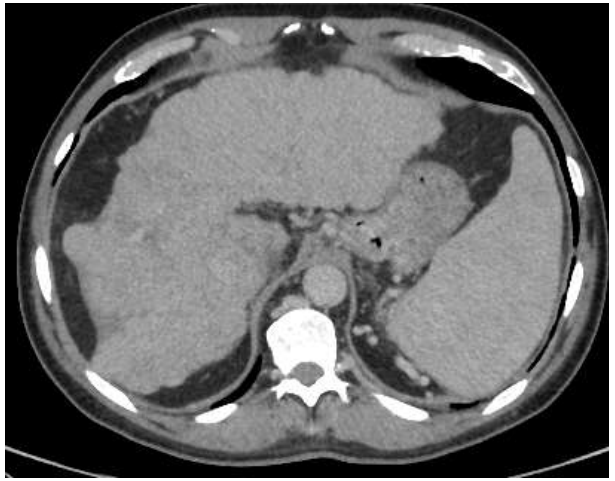
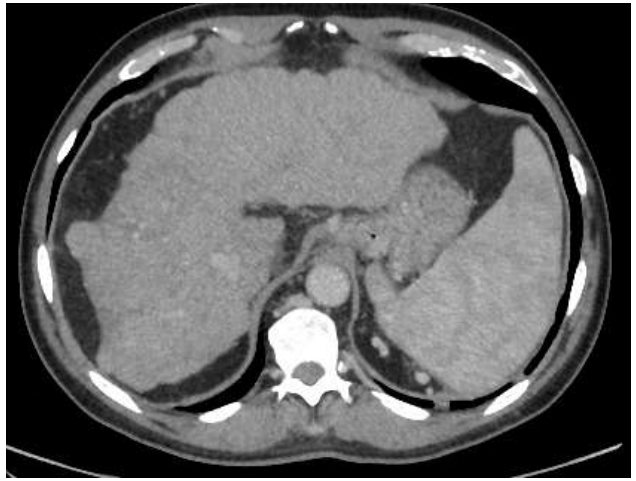
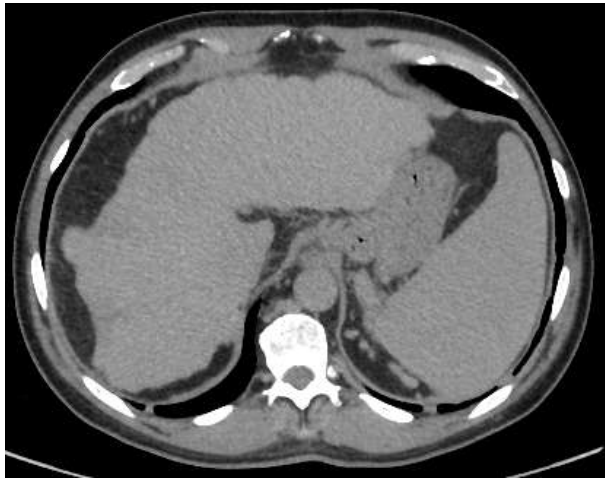

LR-2 - Confluent Hepatic Fibrosis

LR-2 - Confluent Hepatic Fibrosis

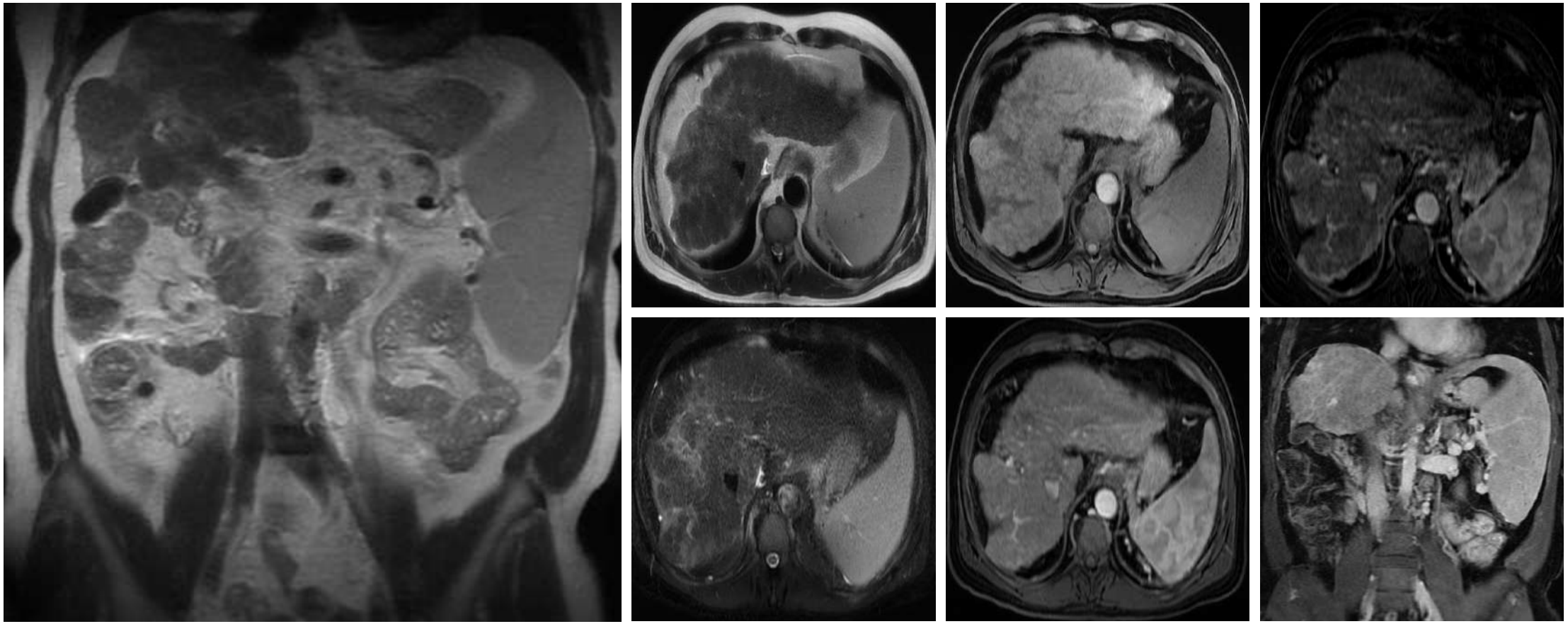

LI-RADS-M

- Probably or definitely malignant, not HCC specific (1/3 are HCC)
  - Bx is needed to establish a diagnosis
  - Targetoid DCE, TP, HBP, DWI
    - Rim APHE
    - Peripheral washout
    - Delayed central enhancement
  - Marked DWI restriction
  - Necrotic, infiltrative
    - No TIV
  - Bile duct dilation
  - Capsular retraction
  - One feature is enough to categorize LI-RADS-M

LI-RADS® v2018
CT/MRI Core

LI-RADS-M

- Associated with bad prognostic features
  - MVI (microvascular invasion) – peripheral ill-defined hypodensity/hypointensity
  - Worse histologic grade - marked DWI
  - Infiltrative growth pattern
  - Portend molecular alterations

Van der Pol, Gastroenterology 2018

LI-RADS-M

- Probably or definitely malignant, not HCC specific
  - Cholangiocarcinoma
  - cHCC-CCA
  - Atypical HCC
  - Metastatic disease
  - Lymphoma, Sarcoma
  - Sclerosed hemangioma

LI-RADS® v2018
CT/MRI Core

LR-M

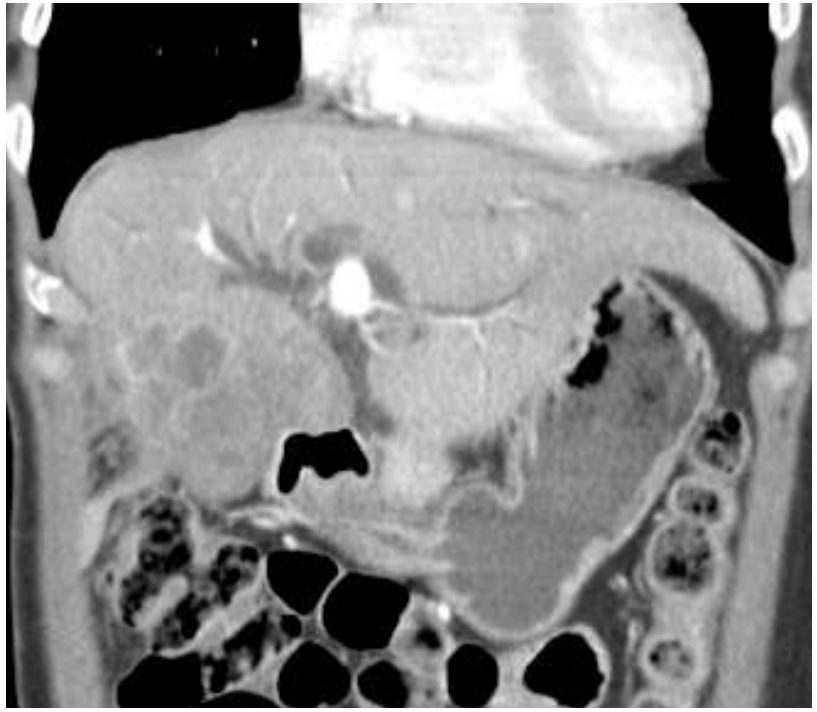

LR-3

CT/MRI Diagnostic Table

Arterial phase hyperenhancement (APHE)		No APHE		Nonrim APHE		
Observation size (mm)		< 20	≥ 20	< 10	10-19	≥ 20
Count additional major features: • Enhancing "capsule" • Nonperipheral "washout" • Threshold growth	None	LR-3	LR-3	LR-3	LR-3	LR-4
	One	LR-3	LR-4	LR-4	LR-4 / LR-5	LR-5
	≥ Two	LR-4	LR-4	LR-4	LR-5	LR-5

LR-4 / LR-5

Observations in this cell are categorized based on one additional major feature:

- LR-4 – if enhancing "capsule"
- LR-5 – if nonperipheral "washout" **OR** threshold growth

If unsure about the presence of any major feature: characterize that feature as absent

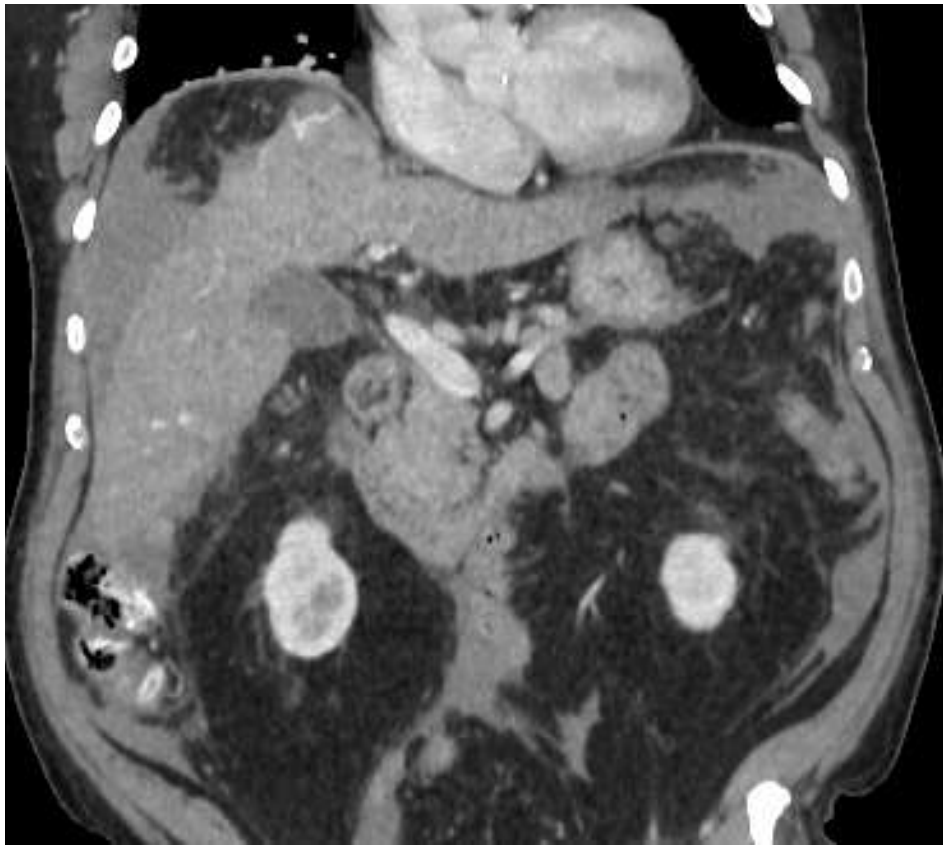

“Liver mass”

HCC; LR-5

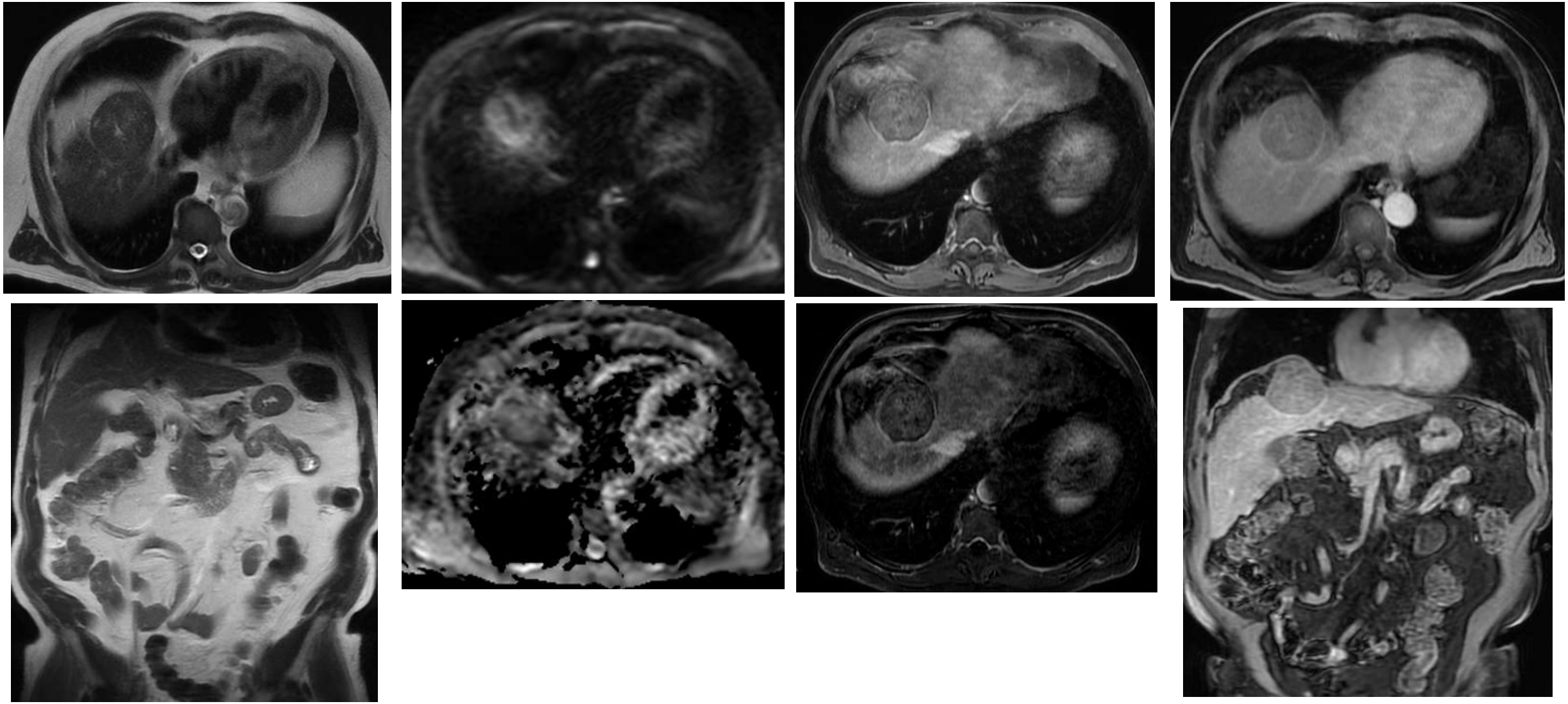

HCCC; LR-5

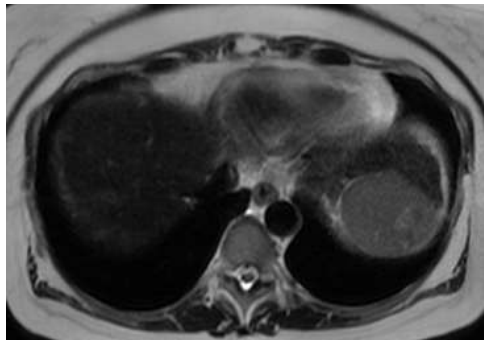

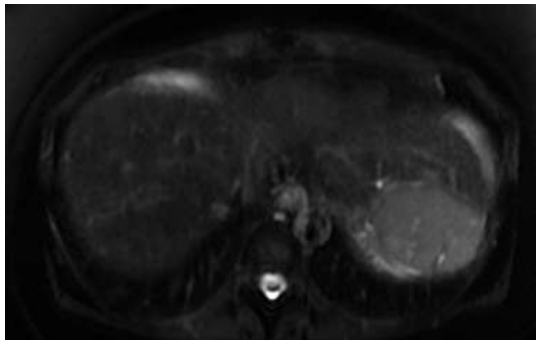

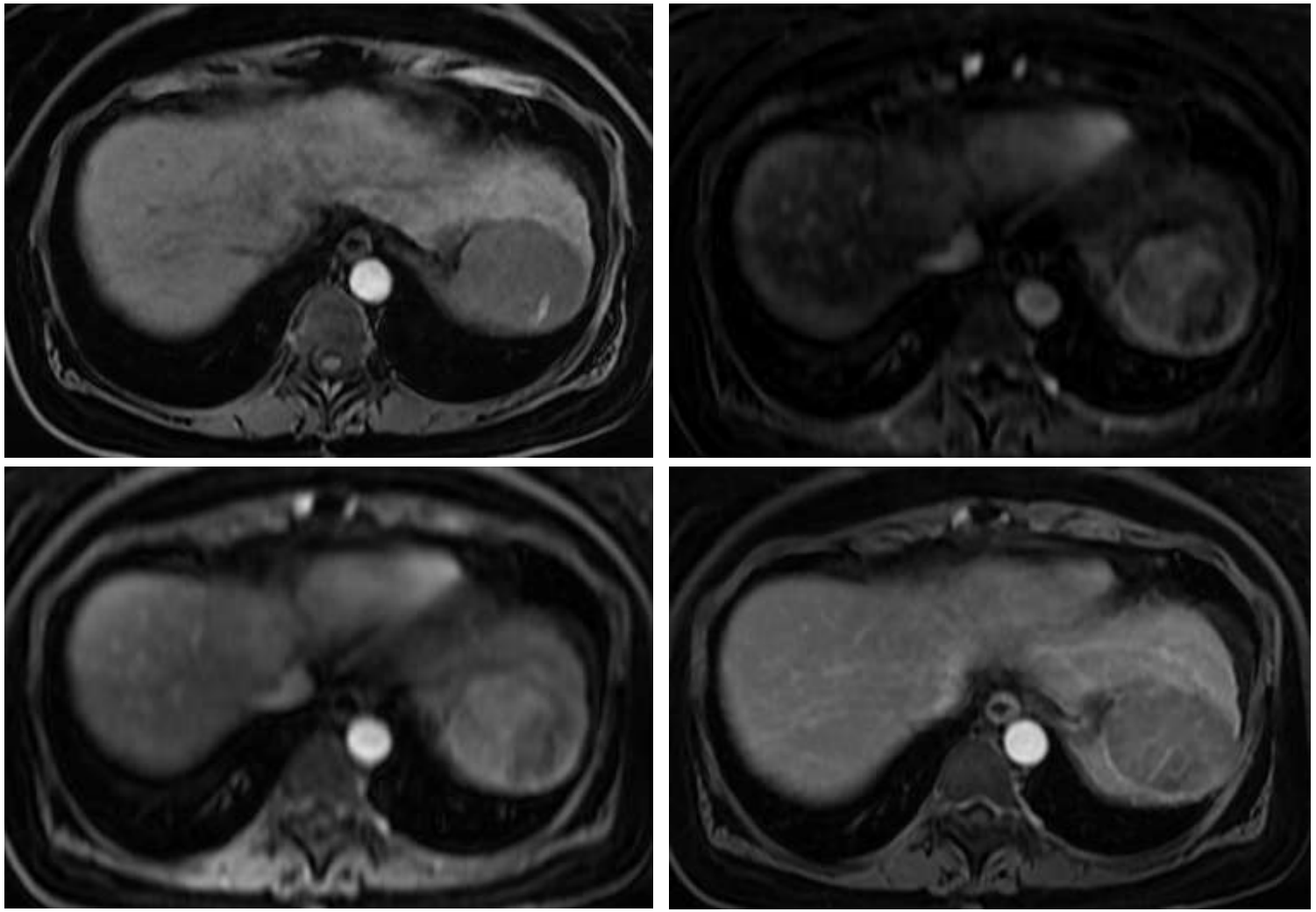

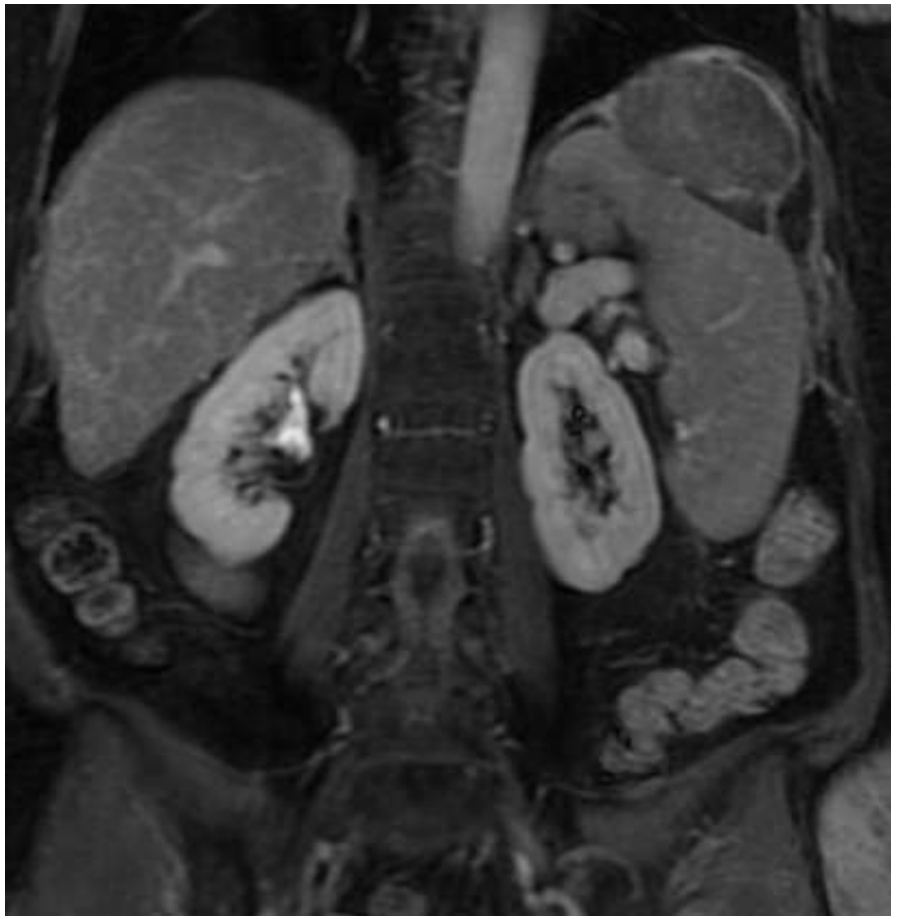

LI-RADS

Step 1. Apply LI-RADS® CT/MRI Treatment Response Algorithm

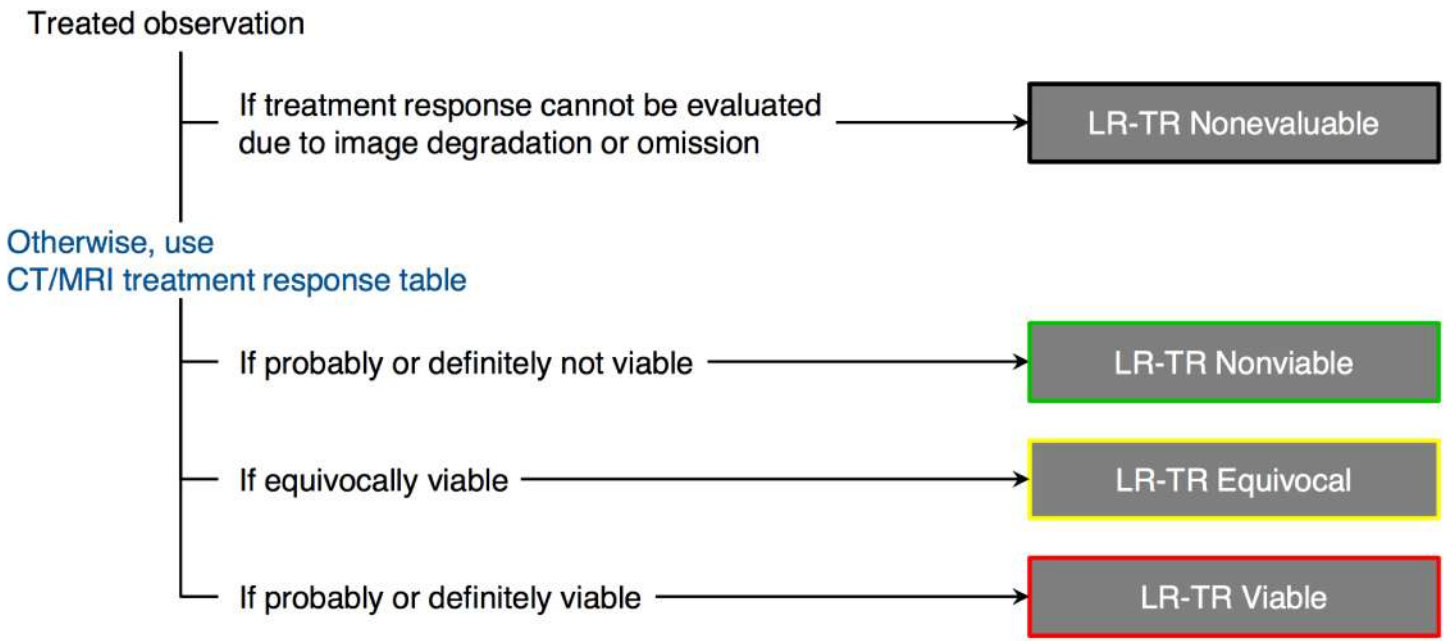

Hepatobiliary contrast (Eovist)

Eovist (Gadoxetate Disodium, Gd-EOB-DTPA)

- Hepatobiliary (hepatocyte-specific) Gd agent
- Uptake requires cellular transporters in functioning hepatocytes
- Focal nodular hyperplasia (FNH)
- HCC
  - 85% - no uptake
  - 15% - uptake (nodule-in-nodule, int septations, int defects, hypo rim)
- HBP hypointensity is not specific for HCC
  - Dysplastic nodule, cyst, hemangioma, mets, iCCa, cHCC-CCA

Suh et al. AJR 2011
Tamada et al. Hepatol Res 2017
Yamamoto et al. AJR 2013
Ichikawa et al. Liver Cancer 2015

Eovist (Gadoxetate Disodium, Gd-EOB-DTPA)

- Eovist in cirrhotic patients
  - Advantages
    - Improved sens for HCC
    - May detect small/early HCCs
    - Predictor of tumor differentiation and improved survival
    - Improved spec for HCC

Suh et al. AJR 2011
Tamada et al. Hepatol Res 2017
Yamamoto et al. AJR 2013
Ichikawa et al. Liver Cancer 2015

Eovist (Gadoxetate Disodium, Gd-EOB-DTPA)

- Eovist in cirrhotic patients
  - Pitfalls
    - Transient sever motion in art phase
    - Mistiming of art phase
    - Washout only in PV phase
    - Require assessment of HBP for adequacy for interpretation
      - TP and HBP onset can be delayed in cirrhosis (poor liver function)
      - Liver iron
      - Severe steatosis
      - Confluent fibrosis

Suh et al. AJR 2011
Tamada et al. Hepatol Res 2017
Yamamoto et al. AJR 2013
Ichikawa et al. Liver Cancer 2015

“Hepatic Mass”

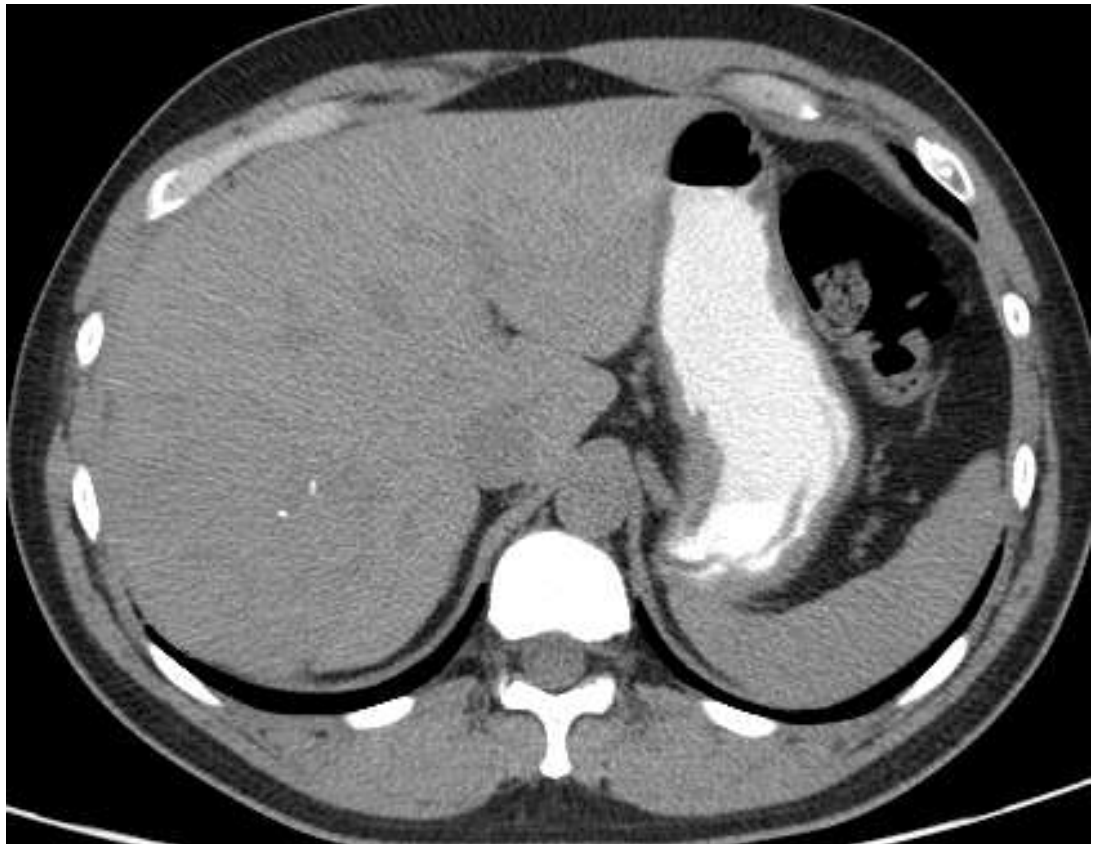

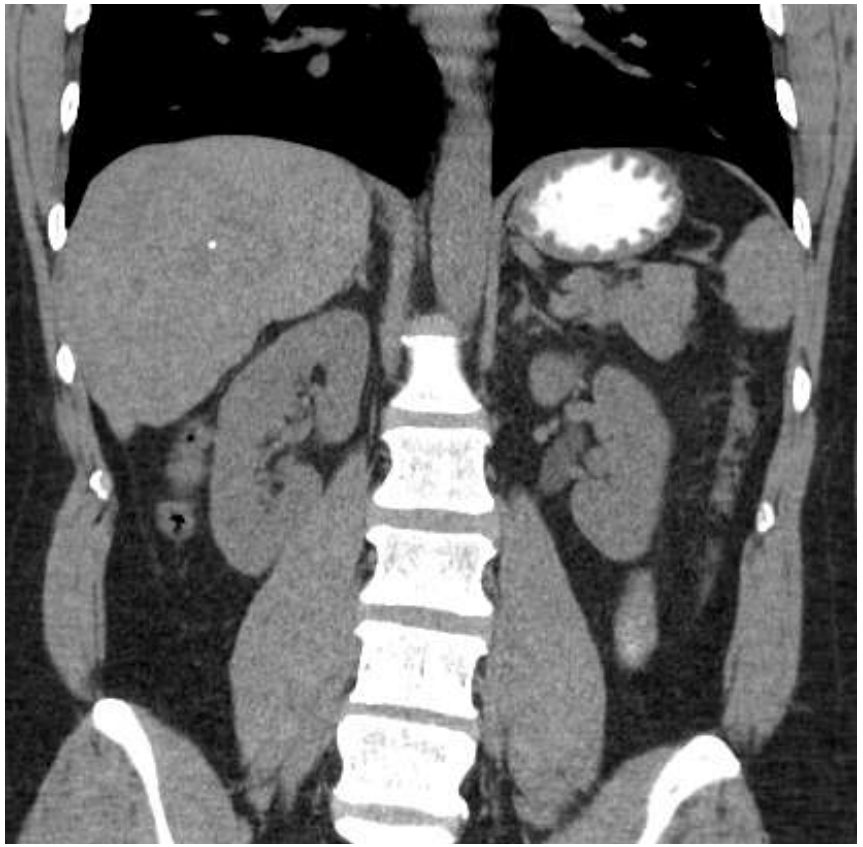

Focal Nodular Hyperplasia (FNH)

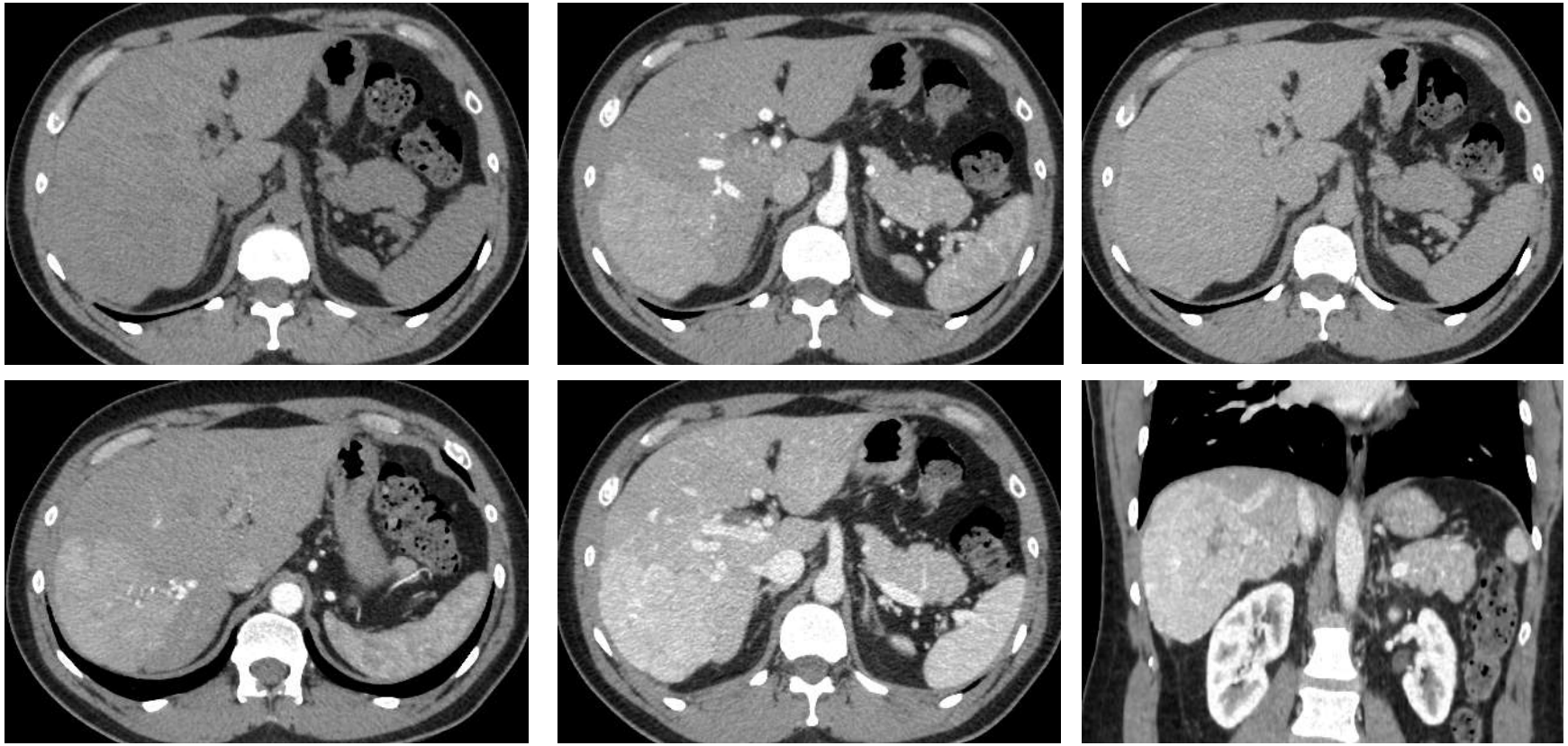

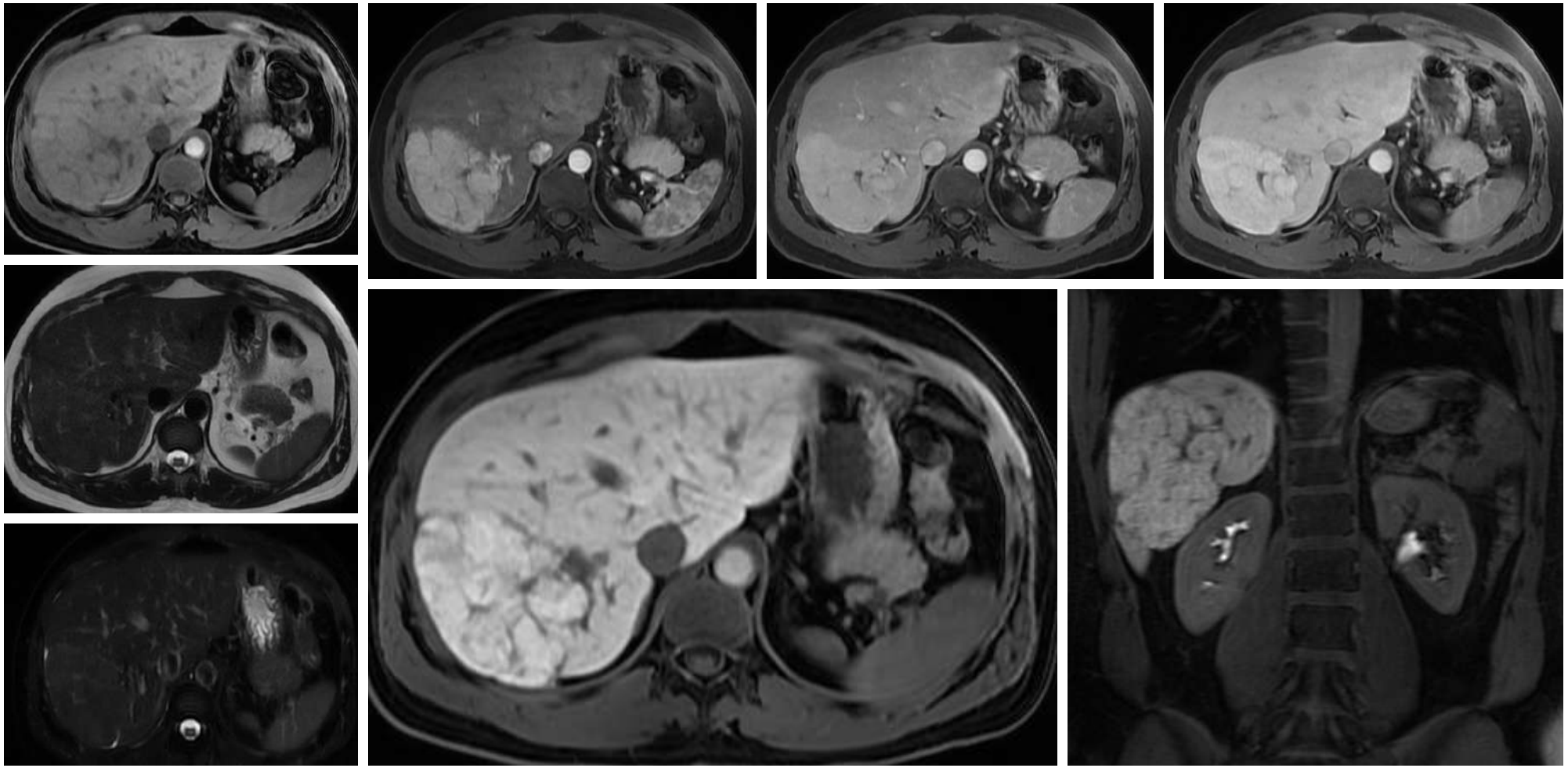

Focal Nodular Hyperplasia (FNH)

Advances in Liver Imaging

State-of-the-art liver imaging in DLD

- Quantitative
  - MRI-PDFF for fat
  - R2* mapping for iron
  - Elastography for fibrosis
- Fast
- Accessible
- Accurate and low risk

NAFLD

MRI (conventional)

- Loss of SI on dual echo opposed-phase compared to in-phase images
  - Qualitative

MRI-PDFF

- Quantitative

MRI-PDFF

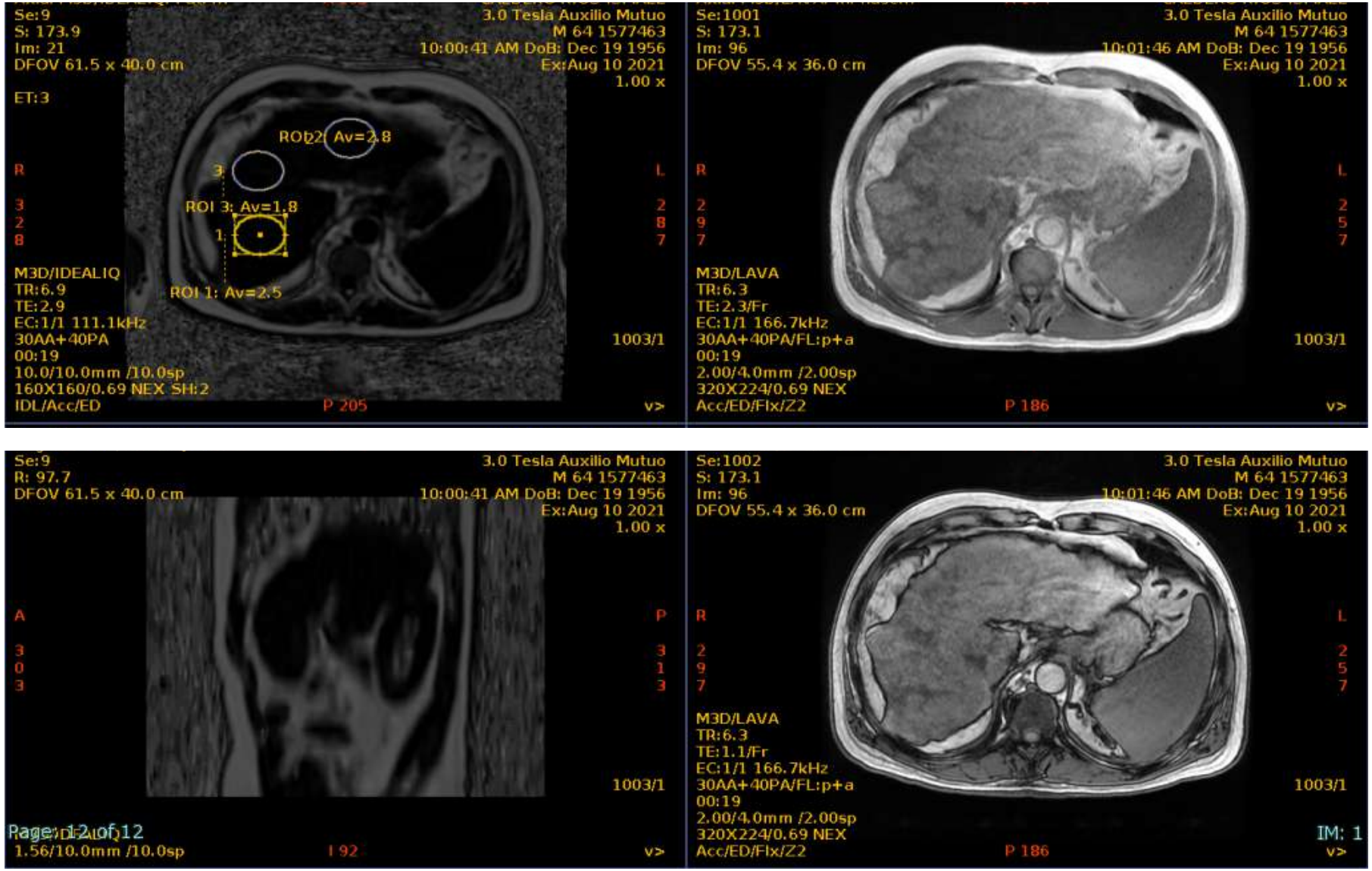
Se:9
S: 173.9
Im: 21
DFOV 61.5 x 40.0 cm
ET:3
3.0 Tesla Auxilio Mutuo
M 64 1577463
10:00:41 AM DoB: Dec 19 1956
Ex:Aug 10 2021
1.00 x
ROI 2: Av=2.8
ROI 3: Av=1.8
ROI 1: Av=2.5
R
L
M3D/IDEALIQ
TR:6.9
TE:2.9
EC:1/1 111.1kHz
30AA+40PA
00:19
10.0/10.0mm /10.0sp
160X160/0.69 NEX SH:2
IDL/Acc/ED
P 205
1003/1
v>
Se:1001
S: 173.1
Im: 96
DFOV 55.4 x 36.0 cm
3.0 Tesla Auxilio Mutuo
M 64 1577463
10:01:46 AM DoB: Dec 19 1956
Ex:Aug 10 2021
1.00 x
R
L
M3D/LAVA
TR:6.3
TE:2.3/Fr
EC:1/1 166.7kHz
30AA+40PA/FL:p+a
00:19
2.00/4.0mm /2.00sp
320X224/0.69 NEX
Acc/ED/Flx/Z2
P 186
1003/1
v>
Se:9
R: 97.7
DFOV 61.5 x 40.0 cm
3.0 Tesla Auxilio Mutuo
M 64 1577463
10:00:41 AM DoB: Dec 19 1956
Ex:Aug 10 2021
1.00 x
A
P
1003/1
Page: 12 of 12
1.56/10.0mm /10.0sp
I 92
v>
Se:1002
S: 173.1
Im: 96
DFOV 55.4 x 36.0 cm
3.0 Tesla Auxilio Mutuo
M 64 1577463
10:01:46 AM DoB: Dec 19 1956
Ex:Aug 10 2021
1.00 x
R
L
M3D/LAVA
TR:6.3
TE:1.1/Fr
EC:1/1 166.7kHz
30AA+40PA/FL:p+a
00:19
2.00/4.0mm /2.00sp
320X224/0.69 NEX
Acc/ED/Flx/Z2
P 186
1003/1
IM: 1
v>

Liver Iron

- Deposition excess in hepatocytes and/or kupffer cells
- As Fe increases, R2* increases
- Liver iron concentration in mg/g dry
- As good or better than liver biopsy
- Detect and quantify iron overload
  - Follow patients on chelation therapy

Hemochromatosis, CLD

R2* mapping

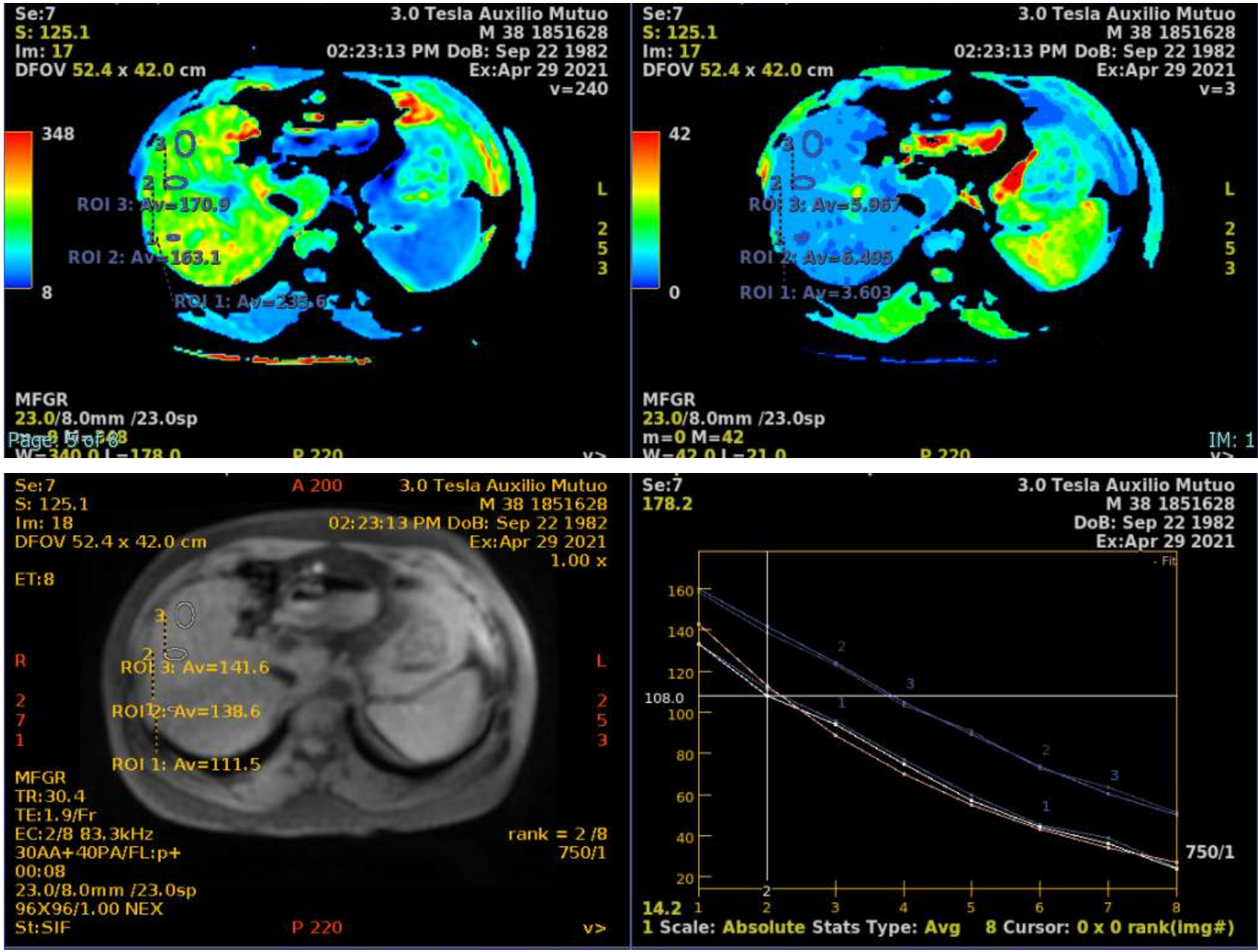
Se:7
S: 125.1
Im: 17
DFOV 52.4 x 42.0 cm
3.0 Tesla Auxilio Mutuo
M 38 1851628
02:23:13 PM DoB: Sep 22 1982
Ex:Apr 29 2021
v=240
348
8
ROI 3: Av=170.9
ROI 2: Av=163.1
ROI 1: Av=235.6
MFGR
23.0/8.0mm /23.0sp
Se:7
S: 125.1
Im: 17
DFOV 52.4 x 42.0 cm
3.0 Tesla Auxilio Mutuo
M 38 1851628
02:23:13 PM DoB: Sep 22 1982
Ex:Apr 29 2021
v=3
42
0
ROI 3: Av=5.967
ROI 2: Av=6.495
ROI 1: Av=3.603
MFGR
23.0/8.0mm /23.0sp
m=0 M=42
IM: 1
Se:7
S: 125.1
Im: 18
DFOV 52.4 x 42.0 cm
A 200
3.0 Tesla Auxilio Mutuo
M 38 1851628
02:23:13 PM DoB: Sep 22 1982
Ex:Apr 29 2021
1.00 x
ET:8
R
L
ROI 3: Av=141.6
ROI 2: Av=138.6
ROI 1: Av=111.5
MFGR
TR:30.4
TE:1.9/Fr
EC:2/8 83.3kHz
30AA+40PA/FL:p+
00:08
23.0/8.0mm /23.0sp
96X96/1.00 NEX
St:SIF
rank = 2 /8
750/1
P 220
v>
Se:7
178.2
3.0 Tesla Auxilio Mutuo
M 38 1851628
DoB: Sep 22 1982
Ex:Apr 29 2021
160
140
120
108.0
100
80
60
40
20
750/1
14.2
1 Scale: Absolute Stats Type: Avg
8 Cursor: 0 x 0 rank(img#)

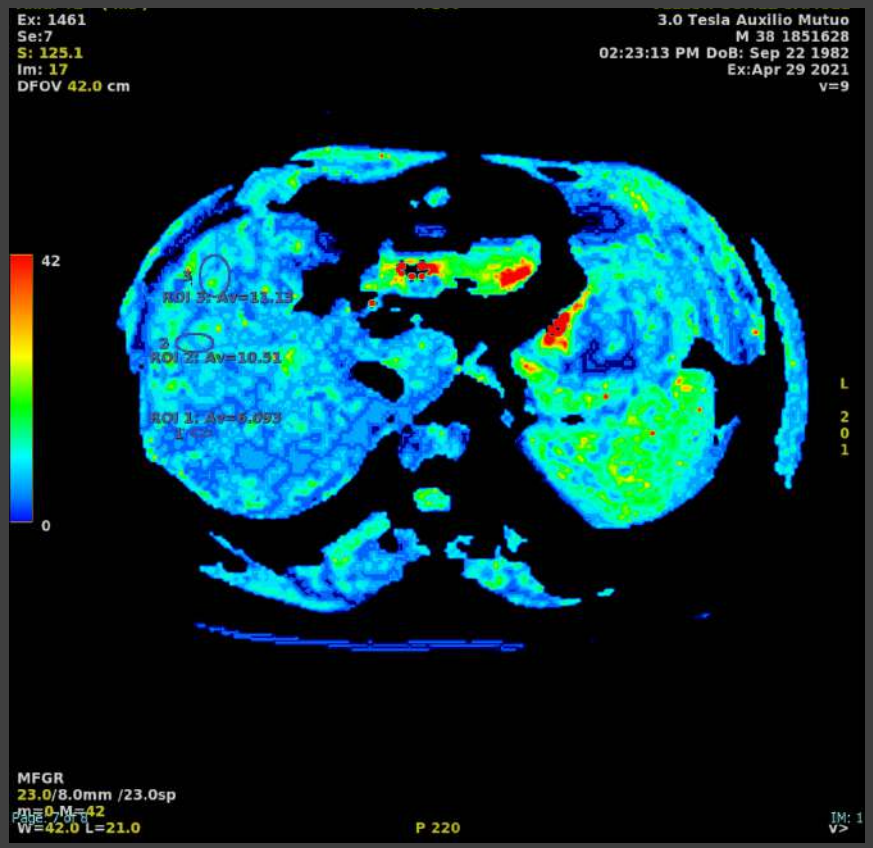
Ex: 1461
Se:7
S: 125.1
Im: 17
DFOV 42.0 cm
3.0 Tesla Auxilio Mutuo
M 38 1851628
02:23:13 PM DoB: Sep 22 1982
Ex:Apr 29 2021
v=9
42
0
ROI 3: Av=11.13
ROI 2: Av=10.51
ROI 1: Av=6.093
L
2
0
1
MFGR
23.0/8.0mm /23.0sp
m=0 M=42
W=42.0 L=21.0
P 220
IM: 1
v>

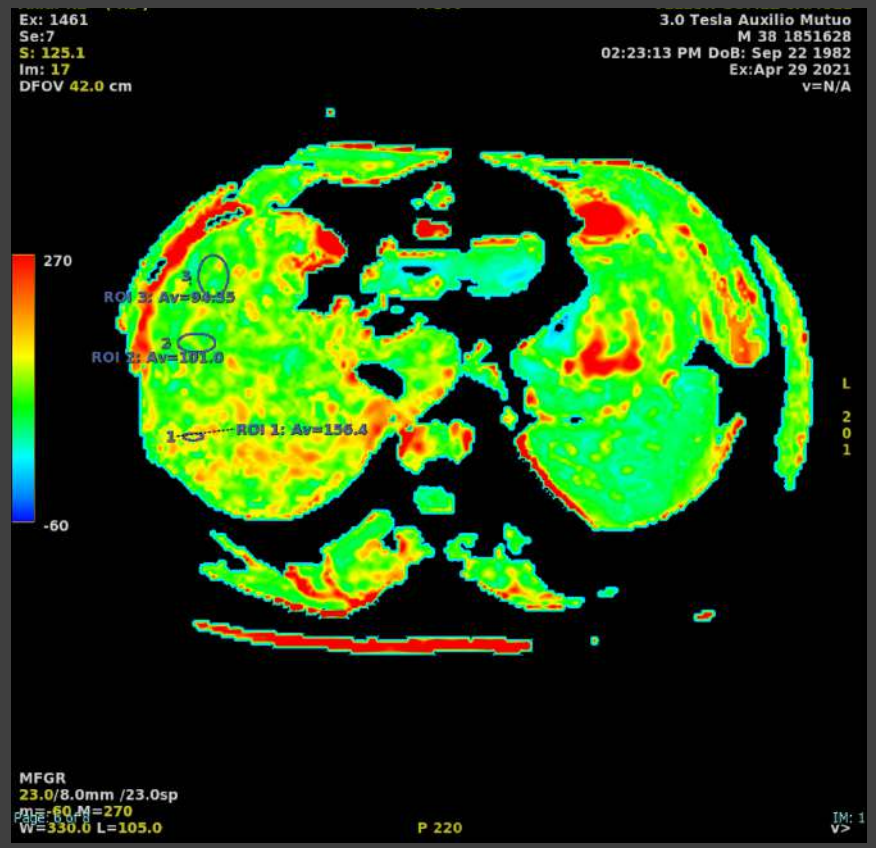
Ex: 1461
Se:7
S: 125.1
Im: 17
DFOV 42.0 cm
3.0 Tesla Auxilio Mutuo
M 38 1851628
02:23:13 PM DoB: Sep 22 1982
Ex:Apr 29 2021
v=N/A
270
-60
ROI 3: Av=94.55
ROI 2: Av=101.0
ROI 1: Av=156.4
L
2
0
1
MFGR
23.0/8.0mm /23.0sp
m=-60 M=270
W=330.0 L=105.0
P 220
IM: 1
v>

R2* mapping

Liver fibrosis

Excess collagen and other macromolecules in extracellular matrix

Too much collagen, collagen in wrong places

Stage 1, 2, 3, 4

Elastography

- Liver stiffness
  - As liver becomes more fibrotic, it becomes stiffer

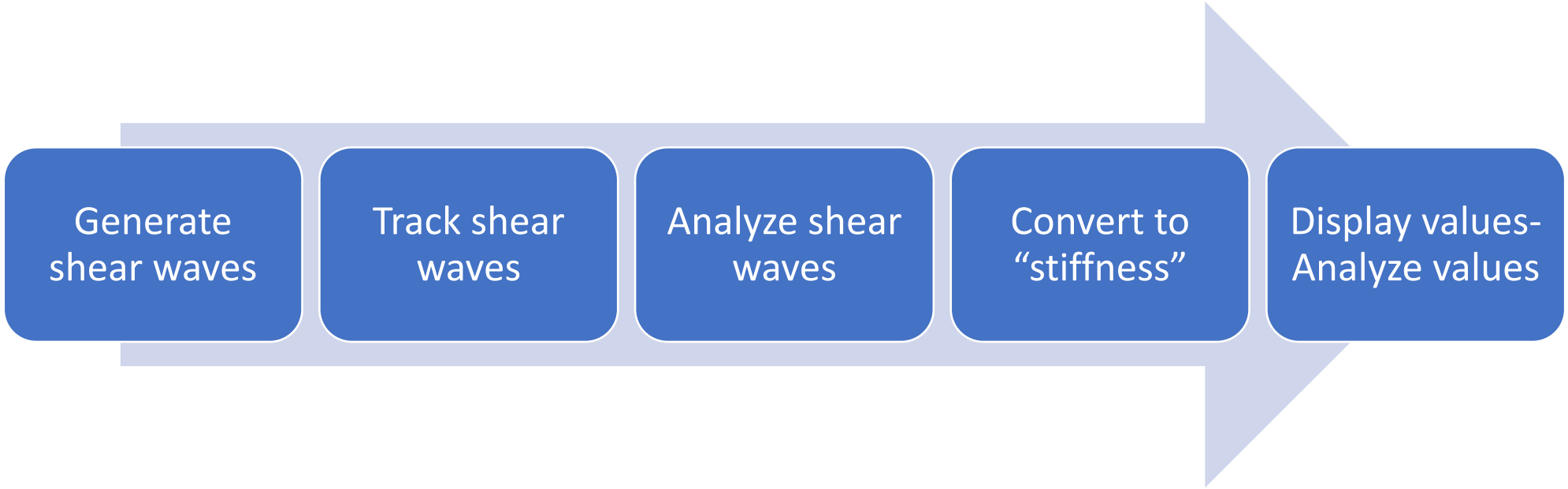

Elastography

- US (strain and shear wave)
  - Elastogram of small ROI
  - Potentially impacted by obesity
  - Poor for early fibrosis (stage 1 vs. stage 2)
  - Ok for stage 2 and up
  - Excellent for detecting Stage 4

- MRI
  - Elastogram of entire liver

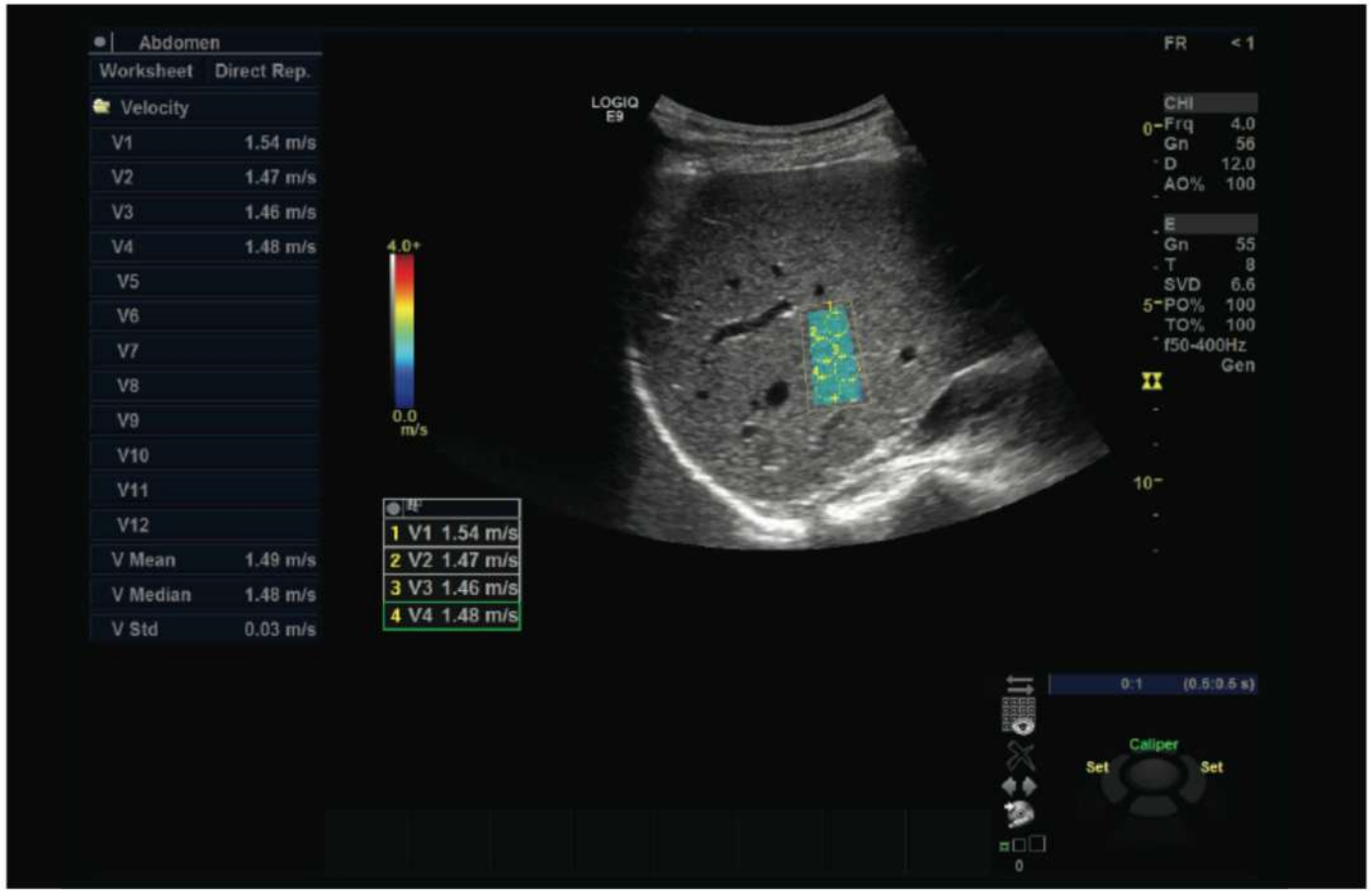

MR elastography

- US vs, MR eslastography
  - MRE more accurate, especially at lower stages

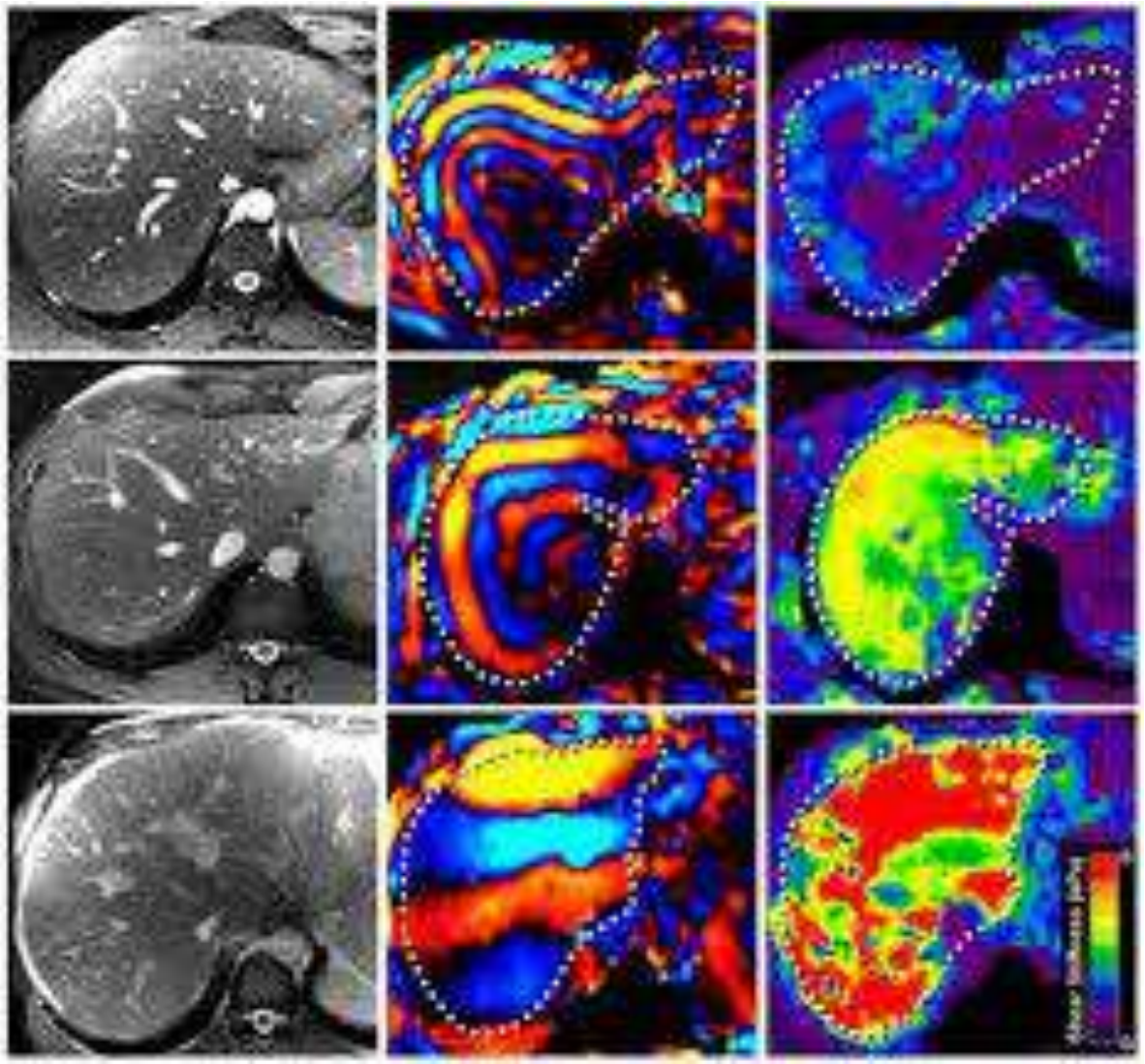

Chen 2017, Park 2017, Imajo 2016, Chou 2017, Cui 2016

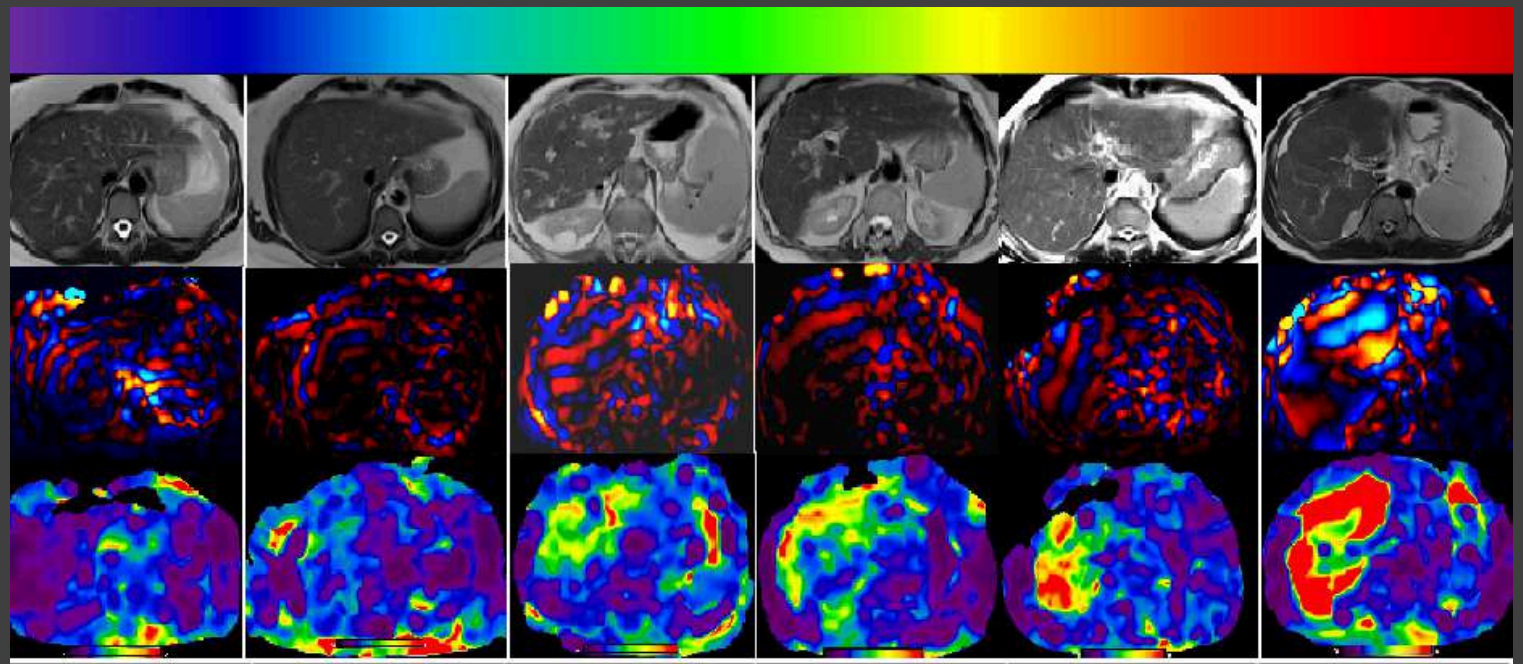

< 2.5 kPa	2.5 - 2.9 kPa	2.9 - 3.5 kPa	3.5 - 4.0 kPa	4.0 - 5.0 kPa	> 5.0 kPa
Normal	Normal or chronic inflammation	Stage 1-2	Stage 2-3	Stage 3-4	Stage 4

MR elastography

Chen 2017, Park 2017, Imajo 2016, Chou 2017, Cui 2016

MRE - Confluent Hepatic Fibrosis

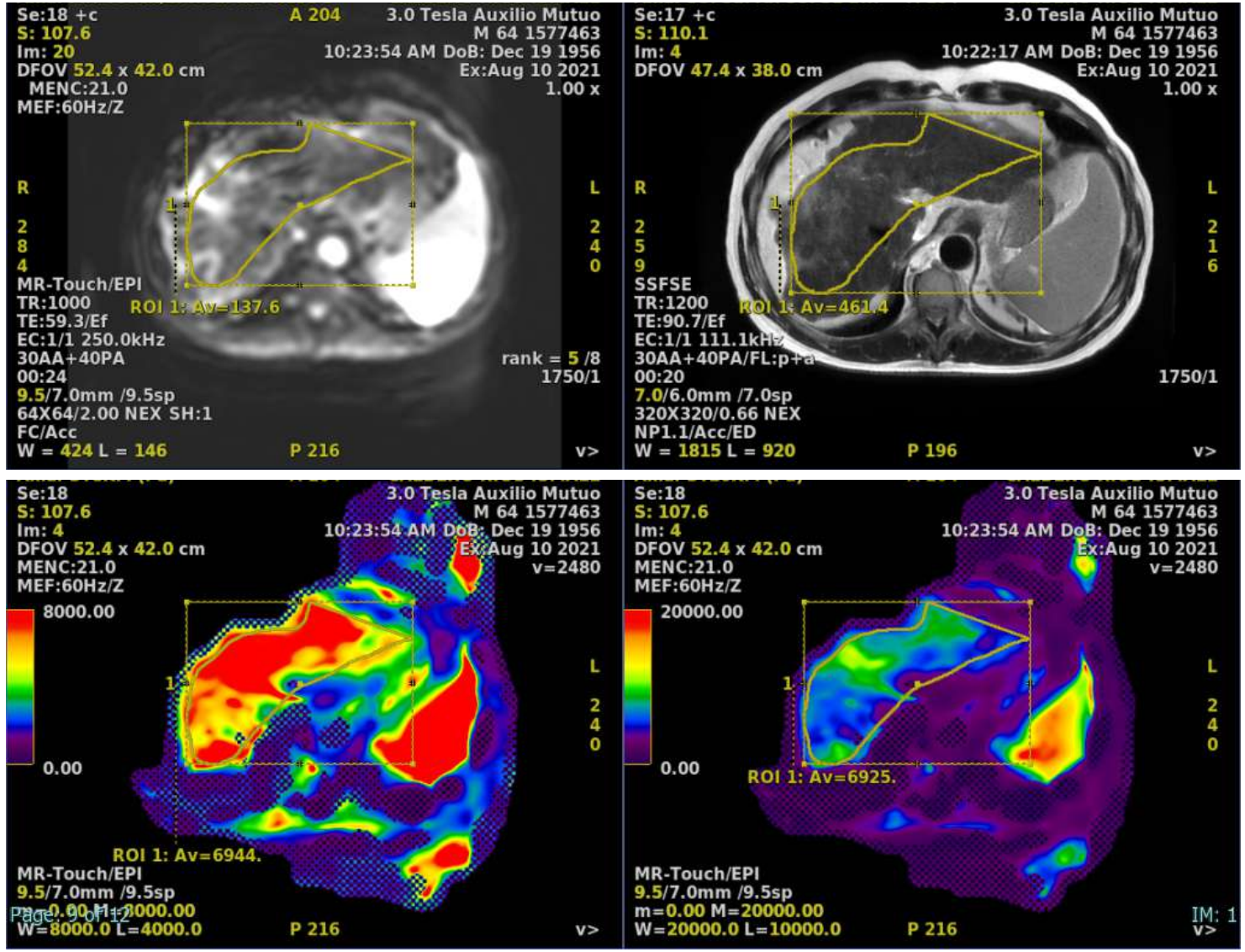

MR elastography

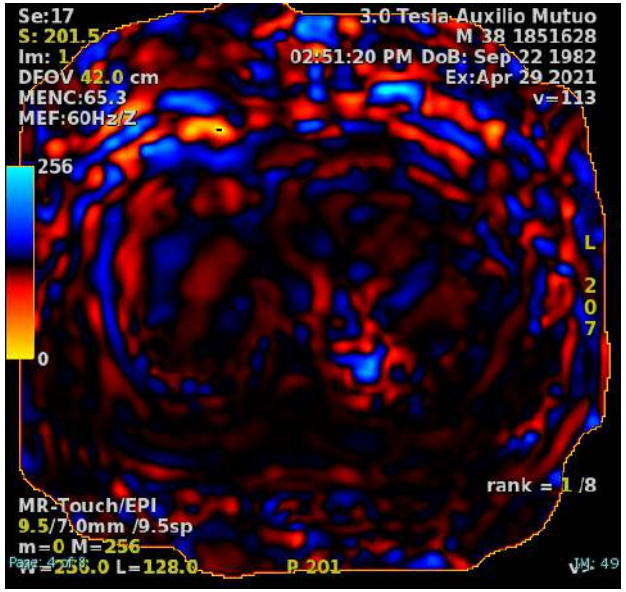

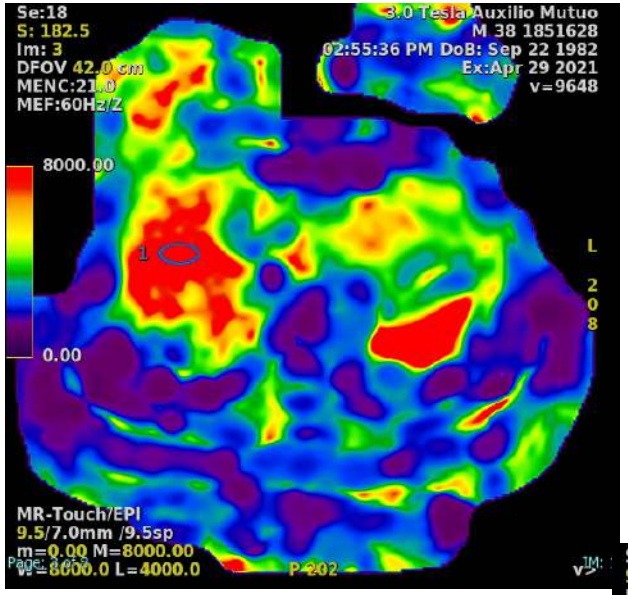

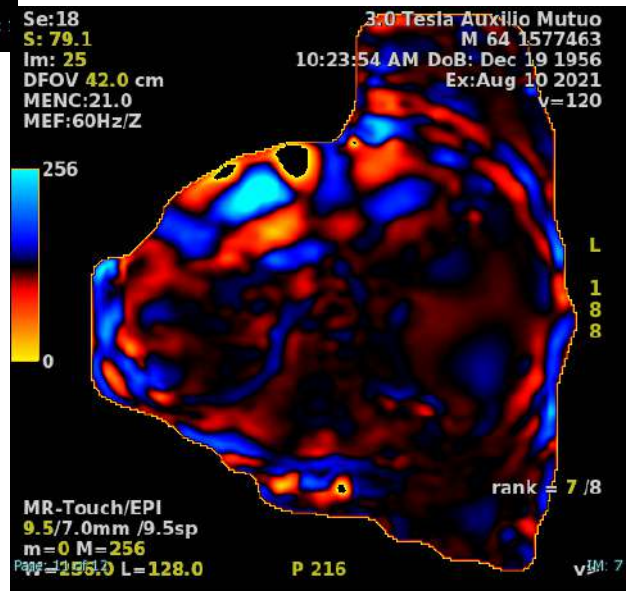

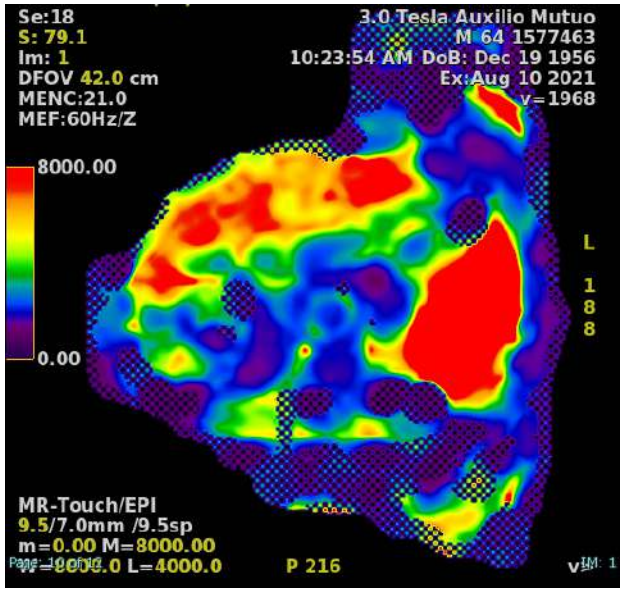

Multidisciplinary team approach

Multidisciplinary Liver Tumor Board

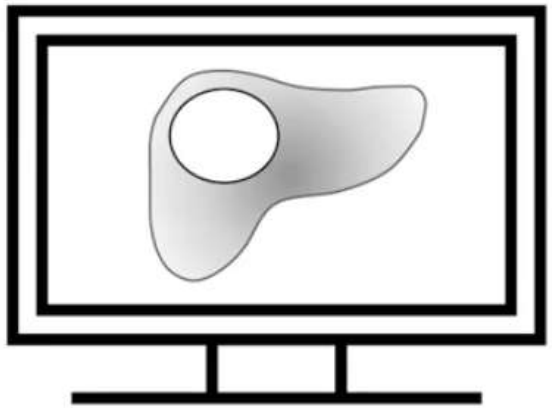

Take home points

Contrast-enhanced CT and MRI play key role in evaluation of the liver in pts at high risk for HCC

- Diagnosis, treatment response

Adequate liver protocol CT/MRI

LI-RADS

Imaging advances in liver imaging

Multidisciplinary approach

Reference

- https://www.acr.org/Clinical-Resources/Reporting-and-Data-Systems/LI-RADS/CT-MRI-LI-RADS-v2018

Thanks…

goryballester@gmail.com